

# Uveitis Society (India)



## NEWSLETTER

---

## January 2020

### From the Desk of the President Dr. Vishali Gupta



Dear colleagues,

It gives me great pleasure in bringing out yet another issue of Newsletter by The Uveitis Society (India) that has been done by the painstaking efforts and enormous amount of hard work put in by Dr. Balamurugan. We are blessed to have him as a lead with all the members of scientific committee who are dedicated to bring out this issue in a very relevant subject that concerns all of us.

I do hope that all of you enjoy reading this. We look forward to your inputs and comments that will help us improve the quality and subject matter. Also look forward to more contributions from all our members.

Wishing you all a very happy 2020



# Uveitis Society (India)

**From the desk of USI Secretary  
Dr. Manisha Agarwal**



Dear Friends,

It gives me and my team immense pleasure in releasing the second issue of the newsletter by Uveitis Society of India. This would not have been possible without the contribution of each one of you and the tireless effort of Dr. Balamurugan. I also would like to thank both national and international faculty who have shared their vast experience in the interesting panel discussions in this issue.

This issue is on a topic which we deal with very often in our clinics and therefore we all hope that reading this issue will enhance the knowledge of each one of us and help in managing our patients.

Hope you all enjoy reading this wonderful newsletter and look forward to your comments and suggestions to make this endeavour of Uveitis Society (India) better and better in future.

Happy reading and a very happy New Year !



# Uveitis Society (India)



**Dr. Narsing A Rao**  
Patron-in-Chief



**Dr. Vishali Gupta**  
President



**Dr. Kalpana Babu**  
Vice President



**Dr. Manisha Agarwal**  
Secretary



**Dr. Sudharshan S**  
Treasurer



**Dr. B Manohar Babu**  
Immediate Past President

## Executive Committee Members



**Dr. Amala E George**



**Dr. Shishir Narain**



**Dr. Padmamalini Mahendradas**

## Advisors



**Prof. Carl Herbort**



**Prof. Amod Gupta**



**Dr. Jyotirmay Biswas**



**Dr. S R Rathinam**



**Dr. Virender S Sangwan**



**Dr. Sudha K Ganesh**

## Scientific Committee Members



**Dr. Reema Bansal**



**Dr. Salil Mehta**



**Dr. S Bala Murugan**



**Dr. Padmamalini Mahendradas**

## Zonal Representatives

**Dr. Subina Narang – North**  
subina\_navya@yahoo.com

**Dr. Debashish Das - East**  
debashisdas@hotmail.com

**Dr. Navneet Mehrotra - West**  
navneetmeh@gmail.com

**Dr. Ankush Kawali – South**  
akawali332@gmail.com

**Dr. Samarendra - Central**  
karkhurs@gmail.com

## From the Editorial Desk...

Dear friends,

Under the aegis of Uveitis Society (India), we are happy to come out with the second edition of newsletter. It is a fruit of a wonderful teamwork that made things realistically possible. We thank all the contributors for meticulously taking up the task and completing the job in time. The reception of the felt topics in uveitis shall propel us to carry on the job to reach greater altitude in the course of time. We thank the felt-group audience who could critically comment on us to make it much better.

Please feel free to contact the editorial team for any queries and clarifications. We are glad to receive many more contributions from all the family members of Uveitis Society (India). It is true that we have all the resources that need to be channelized in a focused direction to the benefit of colleagues. This will translate into patient-centered care for sure!

Au revoir!

**Dr.S.Bala Murugan,**

Chief of Uveitis services,

Aravind Eye Hospital,


Pondicherry-605007

**Email:** drbalamuruganms@gmail.com



# Contents

Sl No	Topic	Author	Page No.
1	<b>The 'Trojan' Bug</b>	Dr. Parthopratin Dutta Majumder	7
2	<b>Delineating differentials of Toxoplasmosis</b>	Dr. Ankush Kawali Dr. Sanjay Srinivasan Dr. Padmamalini Mahendradas	12
3	<b>Toxoplasma Panel Discussion</b>		23
4	<b>The Perplexing Protozoa - Cross Word</b>	Dr. Vinaya Kumar Konana	63
5	<b>An interesting case of ocular toxoplasmosis in 8-year-old child</b>	Dr. Vinaya Kumar Konana Dr. Bhagya M Dr. Kalpana Babu	66
6	<b>What is new in Ocular Toxoplasmosis? A 5-year summary of the published literature (original manuscripts and few important review articles)</b>	Dr. Aniruddha Agarwal Dr. Nitin Kumar Menia Dr. Reema Bansal	71
7	<b>It's not what it seems!: Multiple peripapillary retinitis lesions in Ocular Toxoplasmosis</b>	Dr. Anirudh Soni Dr. Mudit Tyagi	77
8	<b>Role of IgG Avidity test and intravitreal Clindamycin in a pregnant female with ocular Toxoplasmosis</b>	Dr. Lagan Paul Dr. Manisha Agarwal	83
9	<b>Atypical Toxoplasmosis- A review</b>	Dr. Dipankar Das Dr. Tanvi Gupta Dr. Harsha Bhattacharjee	89
10	<b>Constellation of clinical trials done on Ocular toxoplasmosis</b>	Dr. Bharat Gurnani Dr. Kiran Deep Kaur Dr. Pranesh Bala Subramaniam Dr. S Bala Murgan	101
11	<b>Primary acquired Toxoplasma Retinochoroiditis: Clinical Response and Swept-source What is new in the imaging of ocular toxoplasmosis?</b>	Dr. Abhilasha Baharani	116
12	<b>Recent Advances in Ocular Toxoplasmosis</b>	Dr. Aniruddha Agarwal	121
13	<b>UVEITIS UNCODED 2</b>		131
14	<b>IGNITE 2020</b>		132
15	<b>USICON 2019 - Bengaluru</b>		133
16	<b>"Unsung hero of uveitis" by AAO</b>		137
17	<b>USICON 2020 - Hyderabad</b>		138
18	<b>Crossword Answers</b>		139



# The 'Trojan' Bug

Author:

Dr. Parthopratin Dutta Majumder

## The 'Trojan' Bug

**Parthoprathim Dutta Majumder**, Senior Consultant, Department of Uvea & Intraocular inflammation, Sankara Nethralaya, Chennai – 600006, email: drparthoprathim@gmail.com

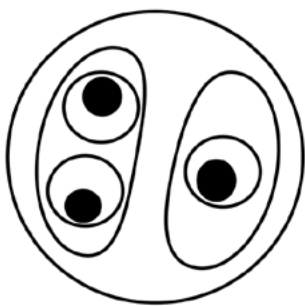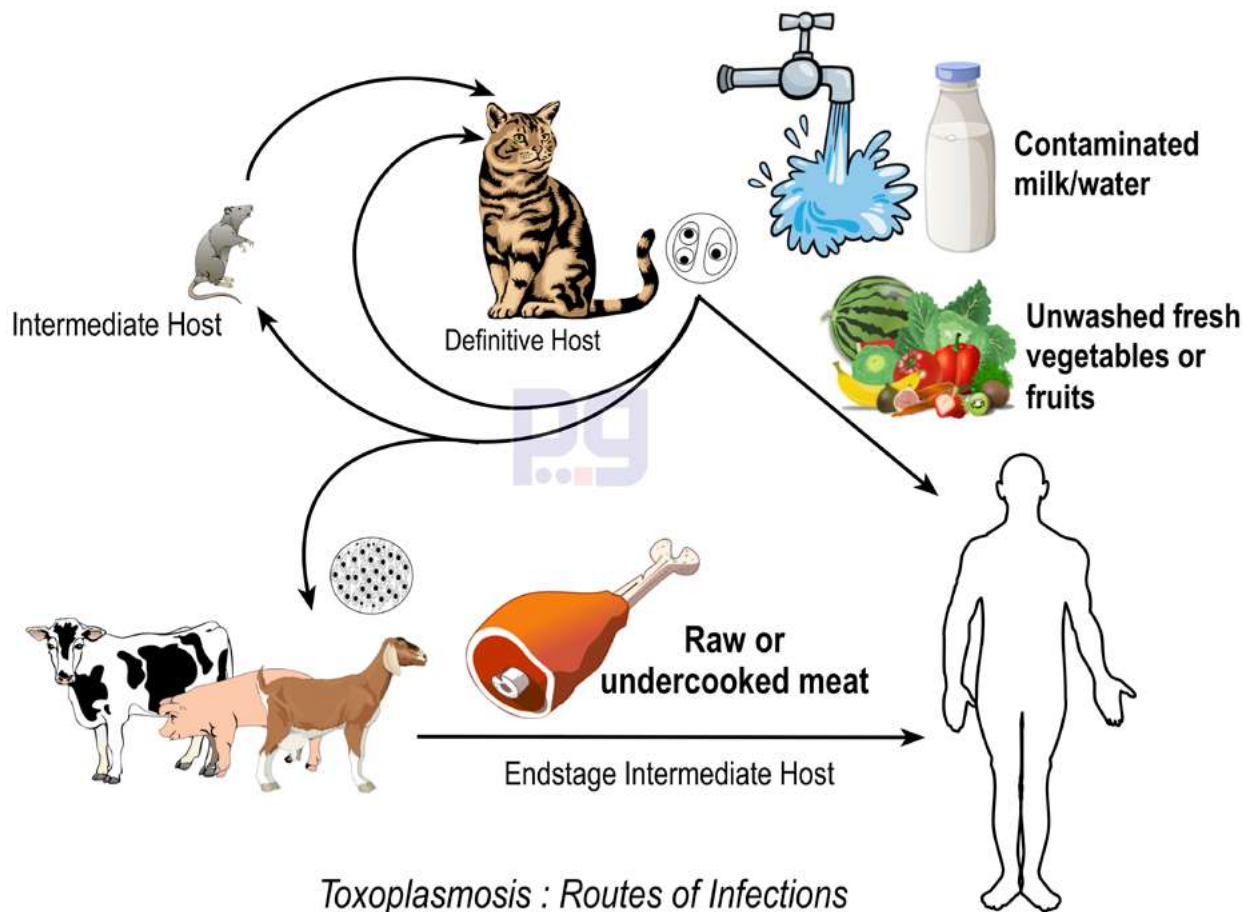
The Trojan Horse is a story from the Trojan War, waged against the city of Troy by the Greeks. After a fruitless siege for 10 years, the Greeks constructed a huge wooden horse and hid few soldiers inside the horse. As the Greeks sailed away and the Trojans came out from the city, celebrating their win and pulled the horse into the city as a victory souvenir. That night the Greek soldiers came out of the horse and opened the gates for the rest of the Greek army, hiding nearby. Thus finally the Greeks won the battle by destroying the city of Troy with the help of Trojan Horse. Thus metaphorically, the term “Trojan Horse” has come to mean any trick or strategy that causes a target to deceive foe by appearance or any other deceptive method reflecting an outwardly benign look or nature. Infection by *Toxoplasma gondii* proceeds according to a “Trojan horse” principle. There are three infectious stages of Toxoplasmosis gondii – the rapidly replicating tachyzoite, the slower-growing bradyzoites (within tissue cysts), and the sporozoites (within oocysts, eggs of the parasite). The Bradyzoites are dormant or sleeping form of the bug which reside within cysts. The tachyzoites are active, rapidly multiplying form of the parasite, primarily responsible for the invasion and wide-spread destruction of the ocular tissue. The primary defense against these tachyzoites is interferon-gamma (IFN- $\gamma$ )-dependent cell-mediated immune response, which can kill off the majority of the tachyzoites.<sup>1</sup> Activation of IFN- $\gamma$ -dependent cell-mediated immune response leads to cocooning of the parasite - tachyzoites are transformed into bradyzoites which in turn form the cysts. These cysts can lie dormant in the retina for a variable time without causing any inflammation or tissue destruction. It has been estimated that each cyst contains between hundreds to thousands of bradyzoites. Cyst formation can occur in any tissue, most frequently observed in neural (central nervous system, retina) and muscular (skeletal and cardiac muscles) tissues. In the eye, the retinal cyst which contains hundred to thousands of bradyzoites lie dormant and are practically immune to destruction by therapeutic agents. Currently, there are no drugs that can kill or eliminate these cysts. <sup>2</sup> Many believe that the organism can alter the behaviour of the immune system of the host and can lie dormant for years. These bradyzoites inside the cyst, like the soldiers inside trojan horse wait for the opportunity to attack the host tissues. Under favorable circumstances, when immune system is weak, they come out from the cyst, get transformed into tachyzoites and invade the ocular tissue. Thus, reactivation of the infection, especially near the old lesion is very common with *Toxoplasma gondii*. Perhaps because of this ‘Trojan Horse’ pattern of attack, this obligate intracellular protozoan parasite is considered as the world’s most successful known parasite.<sup>3</sup> *Toxoplasma gondii* has the ability to infect almost all warm-blooded vertebrates and has a diverse range of hosts. <sup>4</sup> It has been estimated to infect one-third of the global human population with a great variation of prevalence between different countries. The disease burden is higher in developed world. Toxoplasmosis is the second leading cause of death from foodborne illness in the United States and over one million people are infected every year by *Toxoplasma gondii* in Europe.

This banana-shaped parasite was discovered accidentally in 1908 by Nicolle and Manceaux in Tunisia, and by Alfonso Splendore in Sao Paulo, Brazil separately. Nicolle and Manceaux identified the parasite accidentally in a North African rodent, the gundi (*Ctenodactylus gundi*) and Splendore discovered it in rabbit. The parasite was named *Toxoplasma gondii* after the curved shape of its infectious stage (Greek root ‘toxon’= bow). Cat and other members of the family Felidae are responsible for spreading *Toxoplasma gondii* to the environment. They excrete *Toxoplasma gondii* in the form of oocysts with

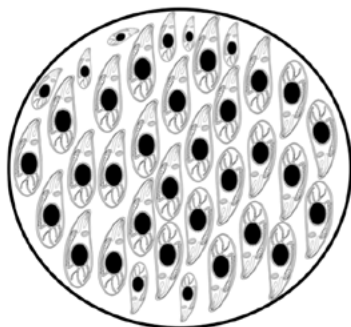


their feces in the environment, which infects human. These oocysts are the eggs of the parasite which contains sporozoites. So human beings can be infected by ingesting soil, water or plant material contaminated with oocysts other than eating undercooked, contaminated meat. Spread of toxoplasma infection from freshwater contamination is a serious and important route of infection and can occur in people, who use unprocessed surface water for consumption.<sup>5</sup> Hall et al. <sup>6</sup> compared *Toxoplasma gondii* antibody prevalence between Jains, vegetarian and non-vegetarian non-Jain Hindus, and other religious groups in a sample of 251 pregnant women, living in Pune. The drinking water was attributed as the main vehicle of toxoplasma infection in Jains, who showed significant high seroprevalence.<sup>6</sup> In another study from South India, municipal drinking water was attributed in a presumed outbreak of toxoplasmosis, which manifested as acquired retinitis in 248 patients.<sup>7</sup> Ocular toxoplasma remains one of the major cause of posterior uveitis in various retrospective studies from tertiary eye care centers from India.<sup>8,9</sup> However, not everybody who gets infected with this parasite, develops ocular manifestation. For example, it is estimated that 1,075,242 persons are infected with toxoplasmosis each year in the United states, but only 21,000 persons are estimated to develop ocular lesions and 4,800 persons per year develop symptomatic ocular lesions.<sup>10</sup> Host genetic factors are believed to play important role in determining the ocular involvement in such patients. <sup>11,12</sup>

Though a great deal of progress has been made, we are yet to fully understand the exact molecular mechanisms behind the pathogenesis of the “Trojan Bug” and develop a drug which can eradicate *Toxoplasma gondii* completely or prevent its recurrence. Even after a century of discovery the “Trojan bug” continues to be menace for the sight saver’s fraternity.



**Oocyst**



**Cyst containing  
Bradyzoites**



**Tachyzoite**

## References:

1. Sturge CR, Yarovinsky F. Complex Immune Cell Interplay in the Gamma Interferon Response during *Toxoplasma gondii* Infection. *Infect Immun*. 2014;82(8):3090-3097. doi:10.1128/IAI.01722-14
2. Alday PH, Doggett JS. Drugs in development for toxoplasmosis: advances, challenges, and current status. *Drug Des Devel Ther*. 2017; 11:273-293. doi:10.2147/DDDT.S60973
3. Sullivan WJ, Jeffers V. Mechanisms of *Toxoplasma gondii* persistence and latency. *FEMS Microbiol Rev*. 2012;36(3):717-733. doi:10.1111/j.1574-6976.2011.00305.x
4. Sibley DL, Charron A, Håkansson S, Mordue D. *Invasion and Intracellular Survival by Toxoplasma*. Landes Bioscience; 2013. <https://www.ncbi.nlm.nih.gov/books/NBK6450/>. Accessed November 20, 2019.
5. Bahia-Oliveira LMG, Jones JL, Azevedo-Silva J, Alves CCF, Oréfice F, Addiss DG. Highly endemic, waterborne toxoplasmosis in north Rio de Janeiro state, Brazil. *Emerg Infect Dis*. 2003;9(1):55-62. doi:10.3201/eid0901.020160
6. Hall SM, Pandit A, Golwilkar A, Williams TS. How do Jains get toxoplasma infection? *Lancet Lond Engl*. 1999;354(9177):486-487. doi:10.1016/s0140-6736(99)02587-8
7. Balasundaram MB, Andavar R, Palaniswamy M, Venkatapathy N. Outbreak of acquired ocular toxoplasmosis involving 248 patients. *Arch Ophthalmol Chic Ill 1960*. 2010;128(1):28-32. doi:10.1001/archophthalmol.2009.354
8. Das D, Biswas J, Ganesh SK. Pattern of uveitis in a referral uveitis clinic in India. *Indian J Ophthalmol*. 1995;43(3):117-121.
9. Rathinam SR, Namperumalsamy P. Global variation and pattern changes in epidemiology of uveitis. *Indian J Ophthalmol*. 2007;55(3):173-183.
10. Jones JL, Holland GN. Annual Burden of Ocular Toxoplasmosis in the United States. *Am J Trop Med Hyg*. 2010;82(3):464-465. doi:10.4269/ajtmh.2010.09-0664
11. Peixoto-Rangel AL, Miller EN, Castellucci L, et al. Candidate gene analysis of ocular toxoplasmosis in Brazil: evidence for a role for toll-like receptor 9 (TLR9). *Mem Inst Oswaldo Cruz*. 2009;104(8):1187-1190. doi:10.1590/s0074-02762009000800019
12. Dutra MS, Béla SR, Peixoto-Rangel AL, et al. Association of a NOD2 gene polymorphism and T-helper 17 cells with presumed ocular toxoplasmosis. *J Infect Dis*. 2013;207(1):152-163. doi:10.1093/infdis/jis640



# **Delineating differentials of Toxoplasmosis**

**Authors:**

**Dr. Ankush Kawali**

**Dr. Sanjay Srinivasan**

**Dr. Padmamalini Mahendradas**

## Delineating differentials of Toxoplasmosis

Ankush Kawali, Sanjay Srinivasan, Padmamalini Mahendradas

Uveitis and Ocular Immunology services, Narayana Nethralaya, Rajajinagar, Bangalore.

A common infection like toxoplasma retinitis, at times can mimic other uveitic entities, when the presentation is atypical. It is of utmost importance to differentiate toxoplasma retino-choroiditis from other infectious and non-infectious conditions at the earliest as the use of steroids without anti-toxoplasma medications may worsen the retinitis, leading to sight threatening irreversible damage.

Herein we have listed few atypical presentations of toxoplasma retino-choroiditis and other closely resembling entities which may delude ophthalmologist.

### Toxoplasma presenting as ARN

**Case 1:** A 52-year-old Indian lady presented with blurring of vision, pain, and redness in her left eye. Best corrected visual acuity was 6/6 in right eye and 6/60 in the left eye. Examination revealed white eye, diffuse granulomatous pigmented keratic precipitates (KPs). (Figure 1a) Through the hazy media temporal peripheral retinitis lesion was made out. B-scan showed doubtful retinal detachment. With working diagnosis of Acute retinal Necrosis (ARN), patient was put on intravenous acyclovir and oral steroids. KPs showed mild resolution but retinitis and vitritis persisted and (Figure 1b, c, d) Anterior chamber tap PCR revealed negative results for HSV, VZV and CMV. Atypical toxoplasma retinitis was suspected. Toxoplasma serology (IgM, IgG both) and aqueous-PCR showed positive results. Patient was switched over to oral Sulfamethaxazole + Trimethoprim (Bactrim-DS) along with oral steroids. Intravitreal clindamycin + dexamethasone injection (n=3) supplemented. After 2 months and uveitis resolved and vision improved, but a month later patient developed rhegmatogenous retinal detachment.

**Figure 1:** Resolving granulomatous diffuse pigmented keratic precipitates (a) sclerosed vessels with retinitis patch approaching towards the macula (b), a satellite lesion of retinitis (c) and diffuse peripheral retinitis in a patient with toxoplasmosis. (case 1)

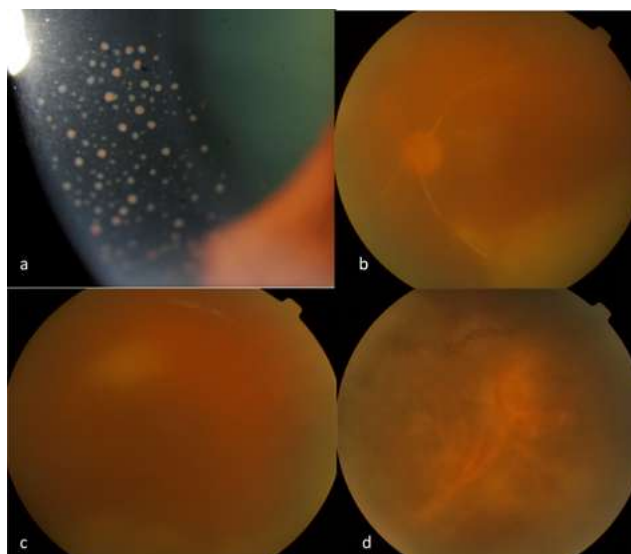


Figure 1-a,b,c,d

The presentation and the course of the disease in this case was of typical ARN but the causative organism was *Toxoplasma gondi*. ARN due to toxoplasmosis has been described in literature.<sup>1</sup> In fact the incidence was reported as high as 62.5%, followed by another rare cause like syphilis (12.5%). Diagnostic Criteria for the ARN laid by American Journal of Ophthalmology clearly mentioned that the designation of ARN syndrome should be based solely on clinical appearance and course of infection and if a causal agent is identified then the retinopathy should be referred to as being caused by the agent.<sup>2</sup>

A peripheral toxoplasma retino-choroiditis when treated inadvertently with steroids may assume the form of a classical viral ARN. Differentiating clinically ARN caused by herpetic viruses and due to toxoplasmosis can be challenging. Both the organisms can cause panuveitis with acute onset. Progression of the retinitis could be slightly rapid when caused by VZV and HSV compared to *Toxoplasma*. ARN when associated with herpes zoster ophthalmicus may present with unilateral headache and the classical skin lesions that will give the important clue towards etiology. Intraocular pressure (IOP) if high, may point towards viral infection. Both the organisms can produce granulomatous KPs (pigmented KPs being common in viral infections), but the presence of stromal keratitis, decreased corneal sensations, iris atrophic changes will suggest herpetic infection. Old, well demarcated, densely pigmented scar along with active retinitis lesions may suggest toxoplasma infection. ARN with optic neuritis is more common with viral infection than toxoplasma. Serology for toxoplasmosis, Goldmann Witmer coefficient and ocular fluid-PCR studies will ultimately differentiate toxoplasma retinitis from viral in a challenging case of ARN.

### Toxoplasma in HIV

**Case 2:** A 52-year-old man, known HIV positive, presented with complaints of blurring of vision in both the eyes. His CD 4 count done 3 months prior to the presentation was 267 cells/ $\mu$ L and patient was on anti-retroviral therapy (ART) for 3 years. Anterior segment examination showed non-granulomatous KPs, 1 + cells in anterior chamber, anterior vitreous face showed 1+ vitritis and fundus examination revealed large retinitis patch almost symmetrical in naso-inferior quadrant in both the eyes. (Figure 2a) SD-OCT scan revealed epi-retinal membrane, retinal thinning, indistinct layers & cavernous retinitis. (Figure 2b) Anterior chamber tap was negative for CMV, but toxoplasma serology (both IgM and IgG) came positive. With intravitreal clindamycin (n=2) and oral Sulfamethaxazole + Trimethoprim retinitis resolved in both the eyes but recurred after 5 months and responded to the same treatment

**Figure 2:** Bilateral almost symmetrical large patches of retinitis in infero-nasal quadrant (a), OCT over the lesion showing epiretinal membrane, full-thickness retinal involvement with empty spaces suggestive of necrosis (cavernous retinitis) (b) in an immunocompromised patient (Case 2).

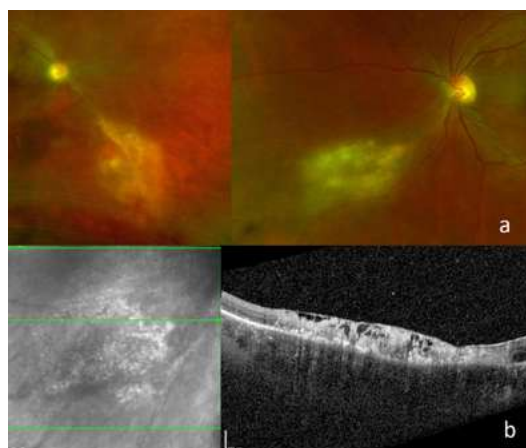
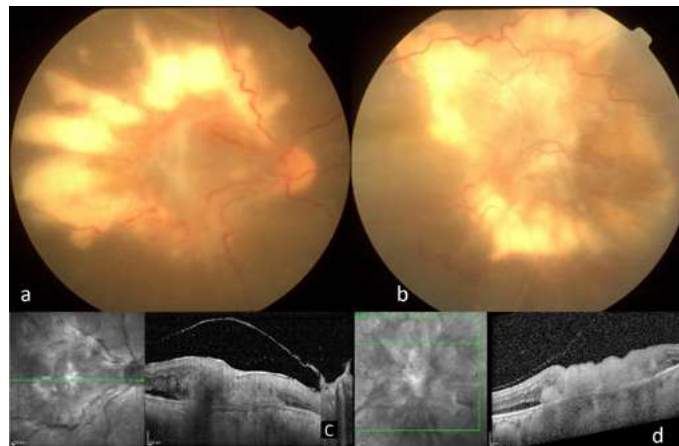


Figure 2 - a & b

**Case 3:** A 39-year-old Indian lady, known HIV positive presented with blurring of vision in her right eye. Examination revealed normal anterior segment in both the eyes. Fundus examination showed vitritis 1+ and a large yellowish retinal lesion at the macula in OD and similar lesion temporal to macula in OS. (Figure 3a, b) SD-OCT scan showed ERM, indistinct retinal layers with full thickness retinal involvement, mild sub-retinal fluid with subretinal exudation and mild choroidal elevation. (Figure 3c, d) CD 4 counts were 184 cells/ $\mu$ L and the patient was on ART. Anterior chamber tap of the right eye, ( since both the eyes had lesions) - PCR tested positive for eubacterium genome, but was negative for panfungal, M. TB and Toxoplasma. Serology (Both IgM and IgG) was positive for toxoplasma. Patient received intra-vitreous clindamycin along with dexamethasone (n=3) and high dose Bactrim-DS (2 TID). Retinitis showed improvement but sub-retinal fluid persisted. Further, patient was lost to follow up.


**Figure 3:** A larger patch of retinitis with feathery extensions in the right eye (a) and a similar patch temporal to the macula in the left eye (b) with central healing and active borders. EDI-OCT scan showing full-thickness retinal involvement with subretinal extension of the lesion with mild serous detachment in an immunocompromized patient with positive toxoplasma serology (IgM and IgG) and positive PCR for toxoplasma suggestive of atypical bilateral toxoplasma retinitis. (Case 3)



**Figure 3 - a, b, c, d**

**Case 4:** A 38-year-old Indian man, presented with complaints of blurring vision in his left eye for 1.5 months. Patient was treated elsewhere with Bactrim and oral steroids, which he had stopped 20 days prior to presentation here. Ocular examination of the left eye revealed non-granulomatous keratic precipitates, 2+ cells in anterior chamber, membranous vitritis, inferior exudates in the vitreous, retinal detachment, subretinal exudates with multiple retinitis patches. (Figure 5) Patient had history of typhoid fever 1 week ago. Investigations came positive for HIV, Toxoplasma serology (IgM and IgG both). PCR for Toxoplasma from aqueous was also positive. CD 4 count was 15 cells/ $\mu$ L. Systemic work up by physician revealed central nervous system involvement. MRI brain showed edematous gyri with severe white matter edema in parieto-temporal lobes suggestive of toxoplasma meningoencephalitis. Patient was treated with sulfadiazine, pyrimethamine with folinic acid and azithromycin. He also received intravitreal clindamycin (n=3). Retinitis resolved but the patient developed RD.

**Figure 4:** Fundus photo showing grade 3 vitreous haze with membranous vitritis and inferior extensive retinitis with exudative retinal detachment in an immunocompromised patient with positive toxoplasma serology (IgM and IgG) and positive PCR for toxoplasma, suggestive of atypical toxoplasma panuveitis. (Case 4)



**Figure 4**

Toxoplasma retino-choroiditis can be atypical in immunocompromised individuals. Bilateral symmetrical, multifocal, large retinitis patches are common in HIV positive patients. In case 2 the lesions simulated CMV-retinitis. Both CMV and toxoplasma may not produce significant vitreous or anterior segment inflammation in immunocompromised patients. Both can have retinal vascular involvement. Kyrieleis type of sheathing have been described for both toxoplasmosis and for viruses,<sup>3</sup> but retinal hemorrhages are relatively common in CMV retinitis than in toxoplasma retinitis. OCT-scan showing choroidal elevation, may suggest toxoplasma retino-choroiditis. Choroidal elevation on OCT scan is not seen in CMV retinitis. Both CMV and toxoplasma causes full thickness retinitis with loss of tissue. OCT features of CMV retinitis have been studied in detail by Invernizzi et al.<sup>4</sup> They described 2 distinct patterns: 1) full-thickness retinitis with choriocapillaris alterations and retinal pigment epithelial thickening and 2) cavernous retinitis characterized by inner retinal hyperreflectivity, large empty spaces in outer nuclear layer, and bridges of retinal tissue. We observed such cavernous retinitis in our patient of toxoplasma retinitis as well (case 2).

Retinal detachment, especially serous RD is even rarer in toxoplasmosis. Subretinal fluid with exudation as seen in case 3 may simulate Choroidal neovascular membrane, endogenous endophthalmitis or rarely even sarcoidosis.<sup>5</sup> Peripheral retinal involvement and extensive circumferential progression as seen in case 4 may suggest ARN. In such atypical presentation of toxoplasmosis one cannot clinically differentiate the disease other uveitic entities but has to rely on laboratory investigations. RT-PCR for toxoplasma B 1 genome is confirmatory, but when not available, toxoplasma serology is also helpful. Even in case of negative IgM, high titers of IgG (200 IU/mL or higher) may suggest toxoplasmal etiology.<sup>6</sup>



## Punctate Outer Retinal Toxoplasmosis

**Case 5:** A 5-year-old Indian immunocompetent girl presented with complaints of blurring vision in her right eye. Examination revealed normal anterior segments in both the eyes. Anterior vitreous face showed 1+ cells in right eye. Fundus examination revealed vitreous membranes, multiple small chorio-retinal scars and 2 active retino-choroiditis lesions. (Figure 5a) Other eye showed a typical congenital toxoplasma macular scar (Figure 5b). Patient was started on Bactrim DS, Azithromycin and later oral steroids were added to which patient responded initially, but after tapering steroid doses the inflammation recurred. Anterior chamber tap PCR was negative for toxoplasma and Mycobacterium TB, but toxoplasma IgG was positive with high titers (>500 IU/mL). Patient was given intravitreal clindamycin(n=1) and oral Bactrim was continued for 4 months and stopped. A month after stopping the treatment patient had relapse again in the same eye and was again put on a long-term oral Bactrim therapy.

**Figure 5:** Wide-field fundus imaging showed multiple chorio-retinal scars and 2 active outer retinitis lesions in right eye with vitritis (a) and a typical congenital toxoplasma macular scar in the left eye (b) in an immunocompetent child (Case 5). Wide field fundus imaging showing resolution of retinitis lesions after a long-term treatment with anti-toxoplasma medications, suggestive of multifocal outer retinal toxoplasmosis in the right eye.

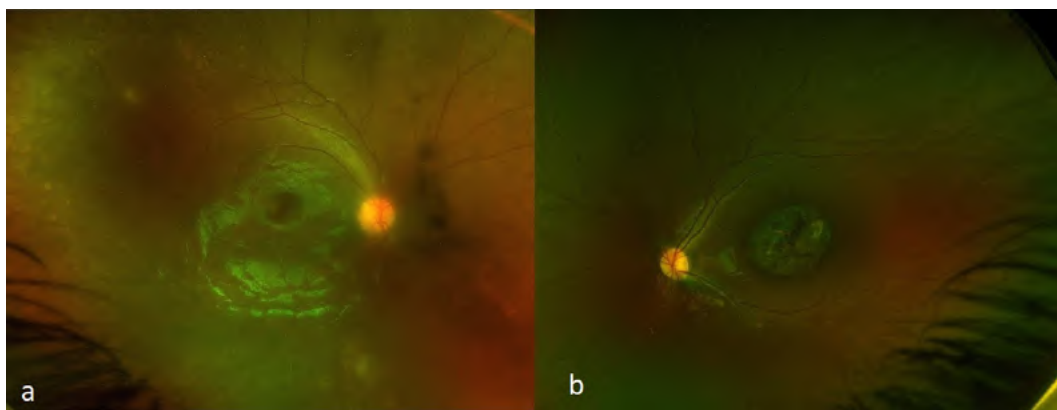
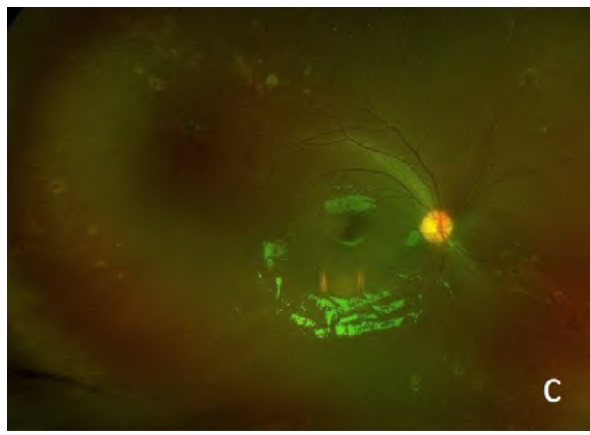


Figure 5a

Figure 5b

Multifocal retino-choroiditis due to toxoplasmosis (Figure 5c) can mimic multifocal choroiditis of tubercular etiology, presumed ocular Histoplasmosis syndrome, punctate inner choroiditis, syphilis and various other white dot syndromes or rarely masquerades.<sup>7</sup> Other eye status may give important clue towards toxoplasmal etiology as in our case 5, but when such clues are absent and when the multifocal retino-choroiditis becomes chronic the case may become challenging to manage. Presence of exudative vasculitis, specially Kyrieleis type of sheathing, if present can help to differentiate above entities from toxoplasma posterior uveitis clinically. Punctate Outer Retinal Toxoplasmosis (PORT) with less pronounced vitritis has been described back in 1985.<sup>8</sup> Such lesions can mimic myriad of white dot syndromes. Finally, its serological and molecular diagnostics as well as the treatment response may differentiate multifocal retino-choroiditis of toxoplasmal etiology from other entities. Chronic or recurrent inflammation as seen in case 5 may require long term maintenance therapy with Bactrim for 20 months.<sup>9</sup>

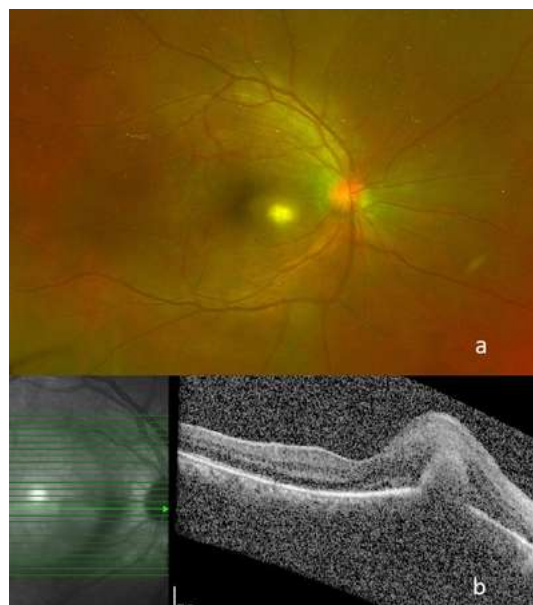


**Figure 5c**

### Uncommon masquerades of toxoplasma retinochoroiditis

**Case 6:** A 37-year-old man presented with history of fever and blurred vision, redness and pain in his right eye for 3 days. Examination revealed congestion, non-granulomatous keratic precipitates, 4+ cells with hypopyon and fibrin. Fundus examination revealed grade 2 vitreous haze and yellowish lesion at the macula with disc hyperemia. (Figure 5a) OCT showed an outer retinal dome-shaped lesion with choroidal elevation. (Figure 5b) Diagnosis of panuveitis was made and endogenous endophthalmitis was suspected with differentials of atypical toxoplasmosis. Anterior chamber tap for smear, culture and PCR for eubacteria and panfungal genome was negative and toxoplasma serology also revealed negative results. After initial unsuccessful treatment with intravitreal clindamycin and oral Bactrim, patient was treated with intravitreal voriconazole, oral fluconazole and oral steroids to which the retinitis responded. Primary site of infection remained unknown. No relapse of inflammation occurred in 1 year of follow up.

Endogenous endophthalmitis is another important differential diagnosis for toxoplasmosis is not only in immunocompromised patients but also in immunocompetent. History of fever or other systemic infection may give clue, but seldom attempts to identify primary site of lesion fails and the case can be confused with toxoplasma retinitis as in case 6. Presence of pain, severe congestion, hypopyon, fibrinous reaction and absence of vasculitis and chorio-retinal scars can point towards endophthalmitis than toxoplasmosis.



**Figure 6**

Epidemic retinitis<sup>10</sup> is yet another differential diagnosis of toxoplasma retinitis, especially in tropical countries like India, when it presents with a single retinitis lesion. History of fever with or without joint pain and skin rash, mild-moderate vitritis, associated macular and disc edema, predominantly inner retinal involvement and absence of choroidal elevation on OCT scan may differentiate epidemic retinitis from toxoplasma retinitis.

Congenital toxoplasma scars can be look-a-like scars due to Zika or Ebola viruses.<sup>11,12</sup> Dense pigmentation of the scar specially at its margins, punched out circular lesion may suggest toxoplasma scar rather than lightly pigmented scars due to Zika or Ebola infection. OCT scan in congenital toxoplasma scar may show severe retinal thinning and choroidal cavitation. Predilection for cells within the Ganglion Cell Layer, hyper-reflective nodular elevations in the outer retina, discontinuation of the ellipsoid zone and hyperreflectivity underlying the retinal pigment epithelium, retinal thinning and choroidal thinning, colobomatous-like excavation have recently been described in Zika virus infection.<sup>11,13,14</sup> Reactivation of infection is common in toxoplasma scars while Zika and Ebola recurrence remains unknown.

North Carolina macular dystrophy (NCMD) is another major differential for congenital toxoplasma scar in west. More ovoid than circular, pigments within the coloboma-like lesion than at the borders, bilaterality and the family history favors the diagnosis of NCMD.

#### References:

1. Balansard B, Bodaghi B, Cassoux N, Fardeau C, Romand S, Rozenberg F, Rao NA, Lehoang P et al. Necrotising retinopathies simulating ARN syndrome BJO 2005; 89:96-101.
2. Holland GN. Standard diagnostic criteria for the acute retinal necrosis syndrome. Executive Committee of the American Uveitis Society. Am J Ophthalmol. 1994 May 15;117(5):663-7.
3. Francés-Muñoz E, Gallego-Pinazo R, López-Lizcano R, García-Delpech S, Mullor JL, Díaz Llopis M. Kyrieleis' vasculitis in acute retinal necrosis. Clin Ophthalmol. 2010;4:837–838.
4. Invernizzi A, Agarwal A, Ravera V, Oldani M, Staurenghi G, Viola F. Optical coherence tomography findings in cytomegalovirus retinitis: A Longitudinal Study. Retina. 2018 38(1):108-117.
5. McMahon JF, Adam MK, Dunn JP. Optical Coherence Tomography and Management of a Retinal Granuloma in Presumed Ocular Sarcoidosis. Ocul Immunol Inflamm. 2018 Aug 10:1-5.
6. Palanisamy M, Madhavan B, Balasundaram MB, Andavar R, Venkatapathy N. Outbreak of ocular toxoplasmosis in Coimbatore, India. Indian J Ophthalmol 2006;54:129-31.
7. Browning DJ, Fraser CM. Primary intraocular lymphoma mimicking multifocal choroiditis and panuveitis. Eye (Lond). 2007 ;21:880-1.
8. Doft BH, Gass DM. Punctate outer retinal toxoplasmosis. Arch Ophthalmol. 1985 Sep;103(9):1332-6
9. Silveira C, Belfort R Jr, Muccioli C, Holland GN, Victora CG, Horta BL, Yu F, Nussenblatt RB. The effect of long-term intermittent trimethoprim/sulfamethoxazole treatment on recurrences of toxoplasmic retinochoroiditis. Am J Ophthalmol. 2002;134:41-6.
10. Kawali A, Mahendradas P, Mohan A, Mallavarapu M, Shetty B. Epidemic Retinitis. Ocul Immunol Inflamm. 2019;27:571-577.

11. De Paula Freitas B, de Oliveira Dias JR, Prazeres J, Sacramento GA, Ko AI, Maia M, Belfort R Jr. Ocular Findings in Infants with Microcephaly Associated With Presumed Zika Virus Congenital Infection in Salvador, Brazil. *JAMA Ophthalmol.* 2016 1;134:529-535.
12. Steptoe PJ, Momorie F, Fornah AD, Komba SP, Emsley E, Scott JT, Harding SP, Vandy MJ, Sahr F, Beare NAV, Semple MG. Multimodal Imaging and Spatial Analysis of Ebola Retinal Lesions in 14 Survivors of Ebola Virus Disease. *JAMA Ophthalmol.* 2018 1;136:689-693.
13. Aleman TS, Ventura CV, Cavalcanti MM, Serrano LW, Traband A, Nti AA, Gois AL, Bravo-Filho V, Martins TT, Nichols CW, Maia M, Belfort R Jr. Quantitative Assessment of Microstructural Changes of the Retina in Infants With Congenital Zika Syndrome. *JAMA Ophthalmol.* 2017 1;135:1069-1076.
14. Kodati S, Palmore TN, Spellman FA, Cunningham D, Weistrop B, Sen HN. Bilateral posterior uveitis associated with Zika virus infection. *Lancet.* 2017 7;389:125-126.
15. Small KW, Vincent AL, Knapper CL, Shaya FS. Congenital toxoplasmosis as one phenocopy of North Carolina Macular Dystrophy (NCMD/MCDR1). *Am J Ophthalmol Case Rep.* 2019;15:100521. Published 2019 Jul 16.

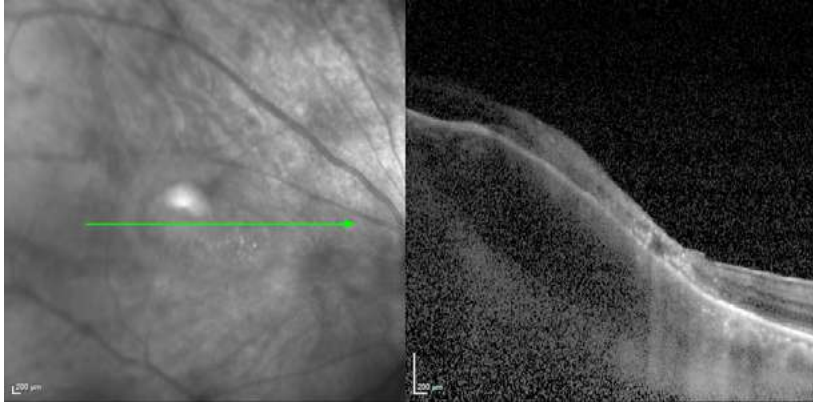

**Table 1: Differentials of toxoplasma uveitis**

	Toxoplasma	ARN of viral etiology	CMV retinitis in immunocompromised	Endogenous endophthalmitis	Epidemic retinitis (retinitis post febrile illness)	Chorio-retinitis of tubercular etiology	Retinal infiltrate in Behcets disease
History	Prior relapses +/- Acute onset, Contact with cats/dogs, contaminated food	Generally, no prior relapses Acute onset	Prior relapses +/- Acute onset	History of fever, systemic infections, acute onset	History of fever with joint pain and skin rash +/-, acute onset	Insidious onset	Insidious onset
Complaints	Blur vision, pain or water	Blur vision, pain +/-	Blur vision, No pain	Blur vision, with Pain and redness	Blur vision, pain/ redness +/-	Blur vision, mild pain/ redness+/-	Blur vision, mild pain / redness+/-
Anterior Segment	Granulomatous > Non-granulomatous KPs +/-, No hypopyon	Decrease in corneal sensation +/-, Diffuse pigmented KPs, iris atrophy+/-	Diffuse KPs+/-, No hypopyon	Hypopyon+/-, Fibrinous reaction+/-, generally non-granulomatous KPs +/-	Non-granulomatous KPs, No hypopyon	Iris nodules/ granuloma +/- granulomatous KPs, Broad based synechia	Mobile hypopyon+/-, Non granulomatous KPs
Posterior segment	Moderate – severe vitritis, generally single retinitis lesion, occasionally associated chorio-retinal scars, frequently associated exudative vasculitis	Circumferential progression, arteriolar vasculitis, Hemorrhages +/-, No dense scarring after resolution	Larger lesions, few hemorrhages, pizza pie appearance, no scarring after resolution	Generally larger lesions arising from choroid and involving outer retina first, vasculitis component is rare	Multifocal lesions, macular edema, mild subretinal fluid, absent clinically evident vasculitis, No scarring after resolution	choroidal or outer retinal lesions, Occlusive vasculitis +/-	Lesions smaller in size, multiple in numbers, can subside without treatment, No scarring after resolution, occlusive vasculitis +/-
OCT	Thick ERM <sup>1a</sup> , Full thickness retinal involvement, choroidal elevation <sup>1b</sup> +/-	Full thickness involvement, necrosis <sup>2</sup> , No choroidal elevation	Full thickness involvement, No choroidal elevation	Choroidal elevation, outer retinal involvement first <sup>3</sup>	No choroidal elevation, Predominantly inner retinal involvement <sup>4</sup>	Ellipsoid zone disruption, choroidal involvement <sup>5</sup>	Intra-retinal infiltration, may not be full thickness, No choroidal elevation
Investigations	IgG, IgM, PCR Toxoplasma B1 genome, goldmann witmer coefficient	PCR HSV, VZV, CMV	PCR CMV	Smear, culture, PCR for bacteria and fungus	Serology and PCR for chikungunya, dengue, west Nile virus, rickettsial organisms	Mantoux, Quantiferon TB gold, Chest and abdominal imaging, Lymph node biopsies, PCR M. TB	HLA B 5 1 Pathergy test

**Figure 6:** Fundus photo showing a focal toxoplasma-like retinitis lesion at the macula (a), but the OCT scan shows a dome-shaped primarily outer retinal lesion with mild choroidal elevation (b) in a patient who did not respond to anti-toxoplasma treatment but responded well to anti-fungal therapy (Case 6).

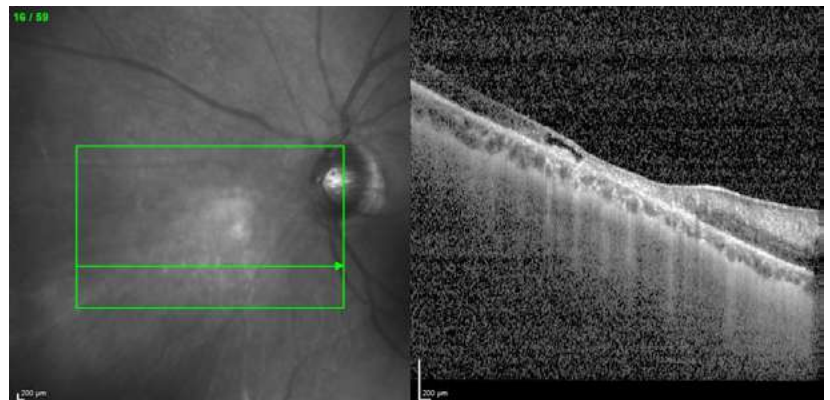
## OCT images

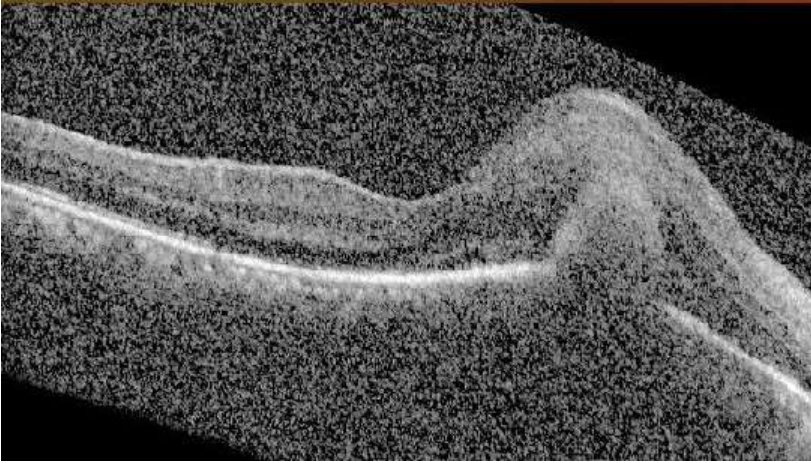
**Figure 1a in  
Toxoplasma retinitis**



**Figure 1b Choroidal elevation in  
toxoplasma retino-choroiditis**

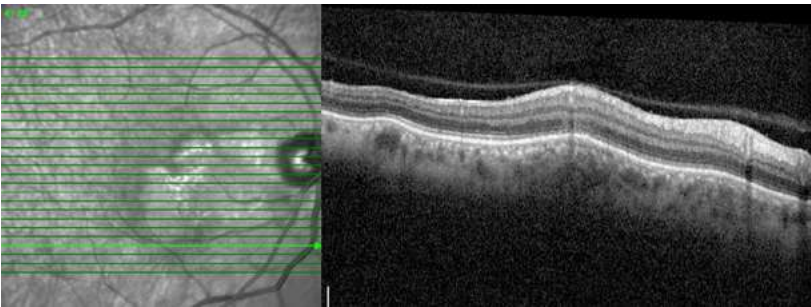
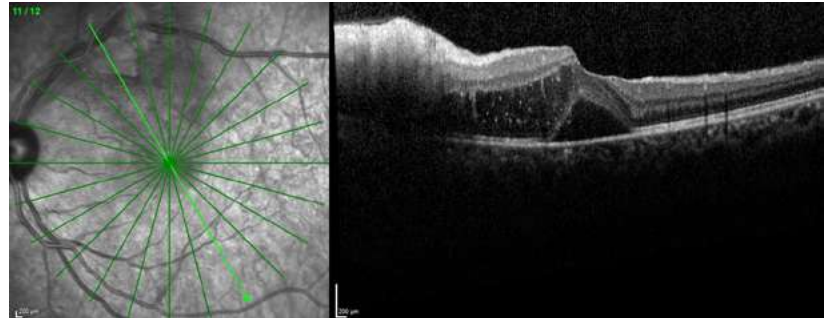
**Figure 2. Full thickness involvement  
with tissue loss in ARN caused by VZV**





**Figure 3** Choroidal and outer retinal involvement in fungal endogenous endophthalmitis

**Figure 4** Predominantly inner retinal involvement in epidemic retinitis.



**Figure 5** Choroidal elevations in tuberculosis



# Toxoplasma Panel Discussion

## Toxoplasma Panel Discussion

### 1. Do you use any diagnostic criteria for ocular toxoplasmosis at all in your practice?

---

#### ➤ Dr. John A. Gonzales

Suspicion for toxoplasma typically occurs due to clinical examination features. We also frequently perform anterior chamber paracentesis in our clinics for any suspected case of infectious uveitis. Thus, we will also check directed polymerase chain reaction (PCR) for toxoplasma. As we also routinely obtain directed serologic or radiographic tests, if we were suspicious of toxoplasma, we would include *Toxoplasma gondii* IgG and IgM

---

#### ➤ Dr. Rupesh Agrawal

I do not use any specific diagnostic criteria in my practice. Its mainly based on my clinical findings and my experience.

---

#### ➤ Dr. Daniel Vitor Vasconcelos-Santos

Diagnosis of ocular toxoplasmosis in our practice is essentially clinical, and based on the typical presentation of focal necrotizing retinochoroiditis, frequently adjacent to a variably pigmented retinochoroidal scar.

---

#### ➤ Dr. Padmamalini M

I make the diagnosis of ocular toxoplasmosis based on the clinical presentation. Serological testing and molecular diagnostic methods help me to confirm the diagnosis of toxoplasmosis. We have classical presentation like head light in the fog appearance in toxoplasmosis. However there are no specific diagnostic criteria for ocular toxoplasmosis.

---

#### ➤ Dr. Mamta Agarwal

- Diagnosis is based on the following:
- Classical Clinical Presentation – Yellowish white retino choroidal lesion with or without adjacent scar and headlight in the fog appearance due to vitreous inflammation

Serological tests – ELISA IgG & IgM

- PCR – *Toxoplasma gondii* – Aqueous & vitreous
  - Ancillary tests – FFA & OCT - mainly for follow ups to note any activity and complications like CNVM, macular edema
-



---

➤ **Avinash Pathengay**

It's a clinical diagnosis.

- i) It causes necrotizing retinitis whether it is in immunocompetent or immunocompromised patients.
  - ii) If Immunocompetent - focal necrotizing retinitis with or without adjacent to scar
  - iii) If immunocompromised – Lesions are larger, bilateral and multifocal
- 

➤ **Dr. B Manohar Babu**

Toxoplasma retinitis is a clinical diagnosis in a vast majority of cases. A unilateral white yellow retinitis with or without an adjacent retinochoroidal scar and vitritis of varying haze- trace to 4+, with or without accompanying anterior segment involvement- KP's, cells and flare

---

2. **You have a patient of toxoplasma suspect: What are the investigations you mandatorily order for? Which investigations do you consider to plan it at a later date?**

---

➤ **Dr. John A. Gonzales**

Please see answer above for investigations. In nearly every case (unless a patient were to refuse) we perform serologic testing as well as an anterior chamber paracentesis.

---

➤ **Dr. Rupesh Agrawal**

Full blood count, toxoplasma IgG and IgM. In selected cases, where diagnosis is not certain – I will do Anterior chamber paracentesis and send the aqueous humor for Tetraplex PCR. I will also get fundus photos and OCT done at initial visit and follow up visits.

---

➤ **Dr. Daniel Vitor Vasconcelos-Santos**

Investigations depend on clinical history and presentation, but tests to exclude other etiologies of infectious posterior uveitis (including syphilis and tuberculosis) are important. In the presence of rapidly progressive large necrotizing lesions, an AC tap to test for herpesviral (and also toxoplasmic) DNA on PCR is highly valuable. In these situations, coinfection with HIV should also be investigated. Overall, toxoplasma serology is mostly supportive if positive (especially in the presence of IgG and IgM), but particularly valuable to rule-out toxoplasmosis if negative (IgG and IgM). A baseline complete blood count is also important, to help monitor myelosuppressive side-effects of therapy.

---

➤ **Dr. Padmamalini M**

Serological testing for Toxoplasma Ig M and Ig G antibodies are ordered mandatorily. Molecular diagnostic methods such as PCR for B1 gene for toxoplasmosis in atypical and diagnostic dilemma cases. Toxoplasma Ig G avidity test in Pregnant women with suspected Toxoplasmosis Repeat serological testing for toxoplasma antibody titres at a later date can be done to assess the response to treatment.

---

➤ **Dr. Mamta Agarwal**

- a. Serum ELISA – Toxoplasma
  - b. ELISA & PCR – aqueous & vitreous samples in case of atypical presentations or non responsive to treatment
- 

➤ **Avinash Pathengay**

IgG and Ig M , (PCR) usually it is available, I have never asked for PCR

---

➤ **Dr. B Manohar Babu**

Toxoplasma serology – ELISA for Toxoplasma IgG and IgM are a must if diagnosis is in doubt. A PCR for Toxoplasma genome B1 and/or 529 bp DNA fragment- when fundus exam is not possible in dense vitritis or atypical lesions, aggressive clinical course, and poor response to Rx

---

### 3. How do you monitor improvement in a hazy view?

---

#### ➤ **Dr. John A. Gonzales**

After starting antimicrobial therapy, if there is still a significant vitritis precluding view to the posterior pole, we will consider starting oral corticosteroids (such as prednisone at 0.5 mg to maximum 1 mg/kg/day dose, though no higher than 60 mg daily).

---

#### ➤ **Dr. Rupesh Agrawal**

Clinically – by assessing Visual acuity and by BIO score.

---

#### ➤ **Dr. Daniel Vitor Vasconcelos-Santos**

Improvement of vitreous haze and inflammatory cell infiltration is to be considered. In addition, the active retinochoroiditis lesion becomes more sharply demarcated, with less surrounding edema and also improvement in local complications such as edema of the macula and/or of the optic disc, perivenular sheathing, etc.

---

#### ➤ **Dr. Padmamalini M**

I follow SUN classification in following up vitreous haze along with healing pattern of retinitis lesions with improvement in visual acuity. If OCT can be obtained, then OCT findings such as disappearance of hyperreflective dots in the posterior vitreous cavity with thickened posterior hyaloid formation along with decreasing retinochoroidal lesion size can also be used to monitor the improvement.

---

#### ➤ **Dr. Mamta Agarwal**

Periodic fundus examination by indirect ophthalmoscopy

---

#### ➤ **Avinash Pathengay**

Photographic documentation

---

#### ➤ **Dr. B Manohar Babu**

Once serology has confirmed diagnosis and oral antiprotozoals under oral steroid cover has been prescribed, weekly reviews of patients is advised- and steroids are tapered only when clinical improvement occurs- lesion regression and clearing of vitreous inflammation

---

---

4. **What is your preferred first line of management when you have toxoplasma high on the differential diagnosis list?**

---

➤ **Dr. John A. Gonzales**

Sulfamethoxazole/trimethoprim or azithromycin

---

➤ **Dr. Rupesh Agrawal**

Azithromycin is my preferred first line. Alternately – Clindamycin. Bactrim DS I use for maintenance. Corticosteroids in all the patients from 2-3 days after initiation of anti toxoplasma therapy.

---

➤ **Dr. Daniel Vitor Vasconcelos-Santos**

We usually opt for classic therapy with sulfadiazine, pyrimethamine and folinic acid, per oral route. When we are not confident of toxoplasma etiology and before the results of immunological tests for other infectious etiologies (particularly syphilis) are available, we defer initiation of systemic corticosteroids.

---

➤ **Dr. Padmamalini M**

First I order diagnostic test for toxoplasmosis and other lab investigations and then i start the patient on systemic antitoxoplasma treatment. After ruling out other infectious causes, I add systemic steroids along with continuation of systemic antitoxoplasma treatment.

---

➤ **Dr. Mamta Agarwal**

Oral clindamycin 300mg qid + Bactrim DS bd + oral steroid

---

➤ **Avinash Pathengay**

Tab Bactrim DS 800mg BD

---

➤ **Dr. B Manohar Babu**

Classic therapy consists of an initial dose of 75 to 100 mg of pyrimethamine daily for two days followed by a 25- to 50-mg dose daily and a 2- to 4-g of sulfadiazine daily for two days, followed by a 500-mg to 1-g dose every six hours as well as 5 mg of folinic acid daily for four to six weeks. Oral prednisolone (1 mg/kg daily) is given from the third day of therapy and tapered over two to six weeks. Alternative treatment regimens include quadruple drug therapy (classic regimen plus clindamycin), as well as single or combined use of clindamycin, trimethoprim/sulfamethoxazole, spiramycin, minocycline, azithromycin, atovaquone and clarithromycin (Soheilian 2011)

---

## 5. Which oral Toxoplasma drug you prefer to start as a first line of therapy?

---

➤ **Dr. John A. Gonzales**

Either sulfamethoxazole/trimethoprim or azithromycin.

---

Dr. Rupesh Agrawal  
As mentioned above.

---

➤ **Dr. Daniel Vitor Vasconcelos-Santos**

Please see above.

---

➤ **Dr. Padmamalini M**

Oral Trimethoprim + Sulfamethaxazole as a first drug, provided that the patient is not allergic to sulpha or I use oral clindamycin as a first drug.

---

➤ **Dr. Mamta Agarwal**

Oral clindamycin 300mg qid + Bactrim DS bd

---

➤ **Avinash Pathengay**

Tab Bactrim DS 800 mg BD

---

➤ **Dr. B Manohar Babu**

• I prefer oral Sulphamethoxazole/Trimethoprim (800mg/160mg) combination (Bactrim DS) BD daily for 6 weeks under oral corticosteroid cover.

Trimethoprim-Sulfamethoxazole versus TripleTherapy- no difference- lesion size, mean improvement in visual acuity, recurrence rates, and adverse events to drug therapy (Soheilian et al 2005).

Trimethoprim is a species-selective DHFR inhibitor is, which is ~50,000-fold selective for the bacterial DHFR over human DHFR (Roth, B. et al. (1987). J. Med. Chem.30, 348–356).

• My second drug of choice is Azithromycin 500 mg OD for 3 days followed by 250 mg OD oral for the same period under steroid cover.

Azithromycin versus TripleTherapy- all the patients responded to treatment in the triple therapy group & 90% of patients responding to treatment in the azithromycin group- (Balaskas K e al 2012.). Useful in patients with sulpha allergy

---

6. **Do you prefer monotherapy with a single anti-toxoplasma or a combination of more than 1 anti-toxoplasma drug with oral steroid medication?**

---

➤ **Dr. John A. Gonzales**

I prefer monotherapy.

---

➤ **Dr. Rupesh Agrawal**

To start with monotherapy, if it does not work – I will go for combination therapy.

---

➤ **Dr. Daniel Vitor Vasconcelos-Santos**

We consider monotherapy for ocular toxoplasmosis as not appropriate (being an exception intravitreal treatment with clindamycin).

---

➤ **Dr. Padmamalini M**

I prefer combination therapy if the lesion is vision threatening along with systemic steroid therapy

---

➤ **Dr. Mamta Agarwal**

Oral clindamycin 300mg qid + Bactrim DS bd + oral steroid

Oral clindamycin 300mg qid + azithromycin 500mg stat followed by 250mg od

---

➤ **Avinash Pathengay**

Combination - Tab Bactrim DS + oral steroid in immunocompetent

---

➤ **Dr. B Manohar Babu**

Monotherapy with oral Bactrim DS works like magic in all cases. In aggressive disease I add oral Azithromycin or inject intravitreal Clindamycin 1 mg/0.1 ml

---

7. **How does imaging help you in ruling out the differentials in dicey scenarios? Please illustrate the readers with your own images if feasible.**

---

➤ **Dr. John A. Gonzales**

OCT can be helpful in identifying toxoplasmosis as a retinal process. If the process involves the choroid exclusively, then I will be suspicious for an etiology other than toxoplasmosis.

---

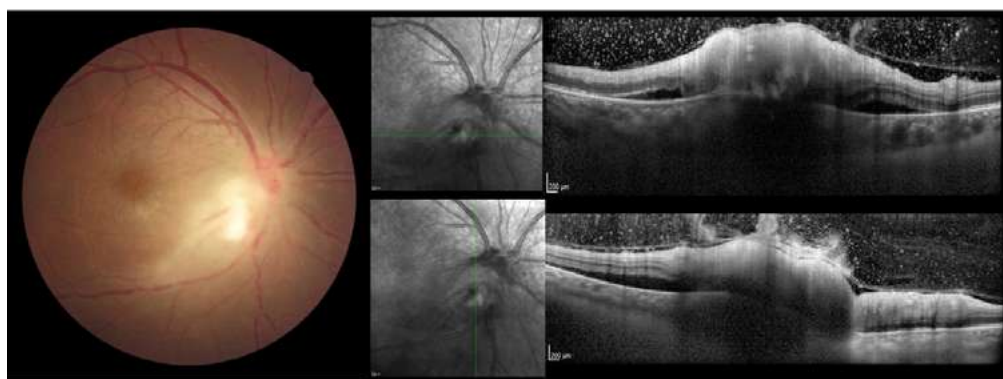
➤ **Dr. Rupesh Agrawal**

Its mostly clinical judgement, imaging helps me in monitoring progress and educating patient about his eye condition. It also helps me in identifying extent of disease.

---

➤ **Dr. Daniel Vitor Vasconcelos-Santos**

Multimodal imaging is extremely helpful in the differential diagnosis, not only to reveal the typical pattern of toxoplasmic retinochoroiditis, but also to disclose other patterns of vitreoretinochoroidal involvement suggestive of other etiologies. (I can provide several examples, if needed).



Fundus photograph (left) and respective horizontal (top right) and vertical (lower right) spectral domain optical coherence tomography sections of an active toxoplasmic lesion close to the optic disc. The typical retinochoroiditis pattern is seen, with focal hyper-reflectivity and disorganization of retinal layers, accompanied by vitreal exudation and fusiform thickening of the underlying choroid. Subretinal fluid can also be seen laterally, medially and inferiorly to the toxoplasmic lesion.

---

➤ **Dr. Padmamalini M**

OCT reveals hyperreflective dots, thickened posterior hyaloid, full thickness retinal hyperreflectivity with choroidal involvement in toxoplasmosis. Cotton wool spots we see inner retinal hyperreflectivity with normal outer retinal layers. In cases of epidemic retinitis we see inner retinal hyperreflectivity with after shadowing. Yes we have included our clinical images with case examples. (please refer the article on differential diagnosis of toxoplasmosis by Kawali et al Page 11 - 21)

---

---

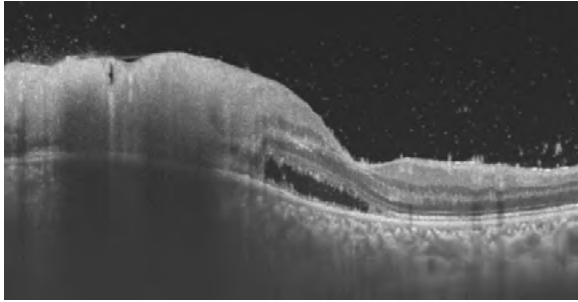
➤ **Dr. Mamta Agarwal**

OCT is extremely helpful in some diagnostic dilemmas. Usually Toxoplasma retinochoroiditis lesions will have a full thickness retinal involvement and also a choroidal involvement. This is different from the OCT appearance of viral retinitis lesions since they predominantly have an initial inner retinal involvement and the choroid is often spared.

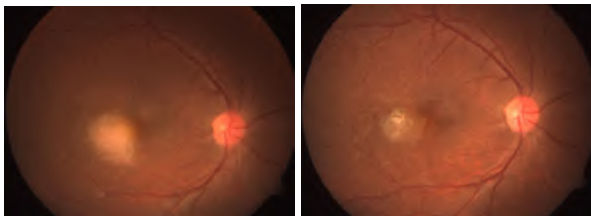
---

➤ **Avinase Pathengay**

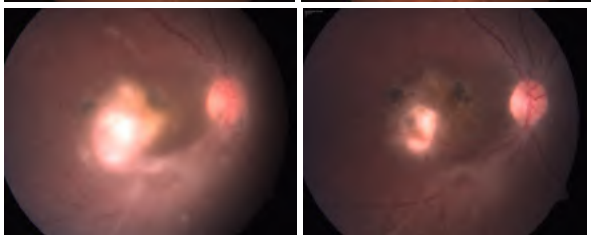
OCT – look for vitreous adhesions , full thickness retinitis involvement



Resolution pattern



Heals with pigmentation



Pattern of healing: Centripetal clearing

---

➤ **Dr. B Manohar Babu**

Classic active ocular toxoplasmosis affects the full-thickness retina with associated vitreous reaction (“light in the fog” appearance), punctate lesions localized in the outer (punctate outer toxoplasmosis) or inner (punctate inner toxoplasmosis) portions of the retina were described by Gass (1968), Friedmann and Knox (1968) and Doft and Gass (1985) introduced the term punctate outer retinal toxoplasmosis(PORT) for the second variant. Imaging can be useful in identifying these entities. (Arch Ophthalmol. 2009;127(10):1390-1394).

---



## 8. What do you do differently in atypical presentations of Toxoplasmosis?

---

### ➤ Dr. John A. Gonzales

In atypical presentations, the serologic or aqueous tests may be expanded. For example, directed PCR for herpetic viruses may be tested (HSV, VZV, CMV) in addition to toxoplasmosis. For conditions manifesting as punctate outer retinal toxoplasmosis, checking HIV status is important.

---

### ➤ Dr. Rupesh Agrawal

AC paracentesis, Vitreous tap if vitreous is significantly inflamed. Do other investigations particularly Tb and syphilis.

---

### ➤ Dr. Daniel Vitor Vasconcelos-Santos

Atypical presentations are more common in immunosuppressed patients and in individuals with recently acquired infection (the latter revealed by high levels of IgM and low avidity IgG). Multifocal and/or large extensive lesions are relatively common in this context. We thus frequently test for HIV coinfection and also tend to tap the AC for PCR for herpesviruses and also for *Toxoplasma gondii*.

---

### ➤ Dr. Padmamalini M

Molecular diagnostic method such as Polymerase chain reaction (PCR) for B1 gene for toxoplasmosis from ocular fluids and or Goldmann – Witmer Coefficient tests are used to confirm the diagnosis. Atypical presentation in an immunocompromised individual with low CD4 count we avoid systemic steroids and we treat the patient with systemic antitoxoplasma treatment with or without intravitreal clindamycin therapy.

---

### ➤ Dr. Mamta Agarwal

In atypical presentations, it is better to rule out all infectious etiology including viral retinitis (herpes simplex, varicella zoster, chikungunya, dengue, cytomegalovirus), toxoplasmosis, tuberculosis, syphilis, rickettsia and fungal retinitis.

Aqueous / vitreous tap – ELISA & PCR – toxoplasma, HSV, VZV, CMV, Chikungunya, dengue  
ELISA HIV, RPR, TPHA

---

### ➤ Avinash Pathengay

Rule out HIV status

---

### ➤ Dr. B Manohar Babu

I get a vitreous tap/biopsy done for PCR analysis for toxoplasma genome along with serology for ELISA IgG/IgM. There have been instances when a media clearing vitrectomy has helped in identifying underlying retinitis suggestive of active ocular toxoplasmosis

---

9. **Juxta papillary Toxoplasmosis! Is it approached anyway differently?  
Please share your expertise...**

---

➤ **Dr. John A. Gonzales**

In such a setting, I am likely to include intravitreal clindamycin.

---

➤ **Dr. Rupesh Agrawal**

I approach it ( and macular involving lesions) more aggressively by admitting the patient and getting all the test done and starting the patient on antitoxoplasma therapy. In patients with risk of vision loss, I will give intravitreal clindamycin.

---

➤ **Dr. Daniel Vitor Vasconcelos-Santos**

When a distinct focus of necrotizing retinochoroiditis is found adjacent to the optic nerve, the differential diagnosis is not different from a similar lesion located elsewhere. However, depending on the degree of reactive optic disc inflammation, the primary retinochoroidal focus may be difficult to define. In this situation, the differential diagnosis expands to other etiologies of neuroretinitis, including Bartonella, among others.

---

➤ **Dr. Padmamalini M**

We treat the patients with antitoxo treatment along with systemic steroids. Here we would like to do OCT and OCTA to rule out any underlying peripapillary CNVM.

---

➤ **Dr. Mamta Agarwal**

Not differently. Same management

---

➤ **Avinash Pathengay**

I don't approach it differently - Only with Oral Tab Bactrim DS along with intravitreal clindamycin and dexamethasone

---

➤ **Dr. B Manohar Babu**

Once the retinitis is clinically suggestive of Toxoplasma Retinitis- management practice is the same.

---

## 10. Intravitreal anti Toxoplasma therapy: Has it changed your practice pattern?

---

### ➤ Dr. John A. Gonzales

Not significantly, unless there are juxtapapillary or macular lesions.

---

### ➤ Dr. Rupesh Agrawal

Nope.

---

### ➤ Dr. Daniel Vitor Vasconcelos-Santos

I only rarely employ intravitreal therapy for toxoplasmosis, as in my experience, its indications are very limited.

---

### ➤ Dr. Padmamalini M

Yes we use intravitreal clindamycin in cases which are refractory to conventional therapy or contraindications to systemic antitoxoplasma therapy.

---

### ➤ Dr. Mamta Agarwal

I still prefer oral anti toxoplasma therapy except where it is contraindicated like pregnant females or patient is intolerant to oral therapy

---

### ➤ Avinash Pathengay

Yes

- i. When disc and fovea are involved
  - ii. Pregnant female
  - iii. Intolerant and non-compliant to oral meds
  - iv. Immunocompromised status
- 

### ➤ Dr. B Manohar Babu

Yes, as mentioned earlier - when diagnosis confirmed by serology- but fundus exam is not possible in dense vitritis or atypical lesions, aggressive clinical course, and poor response to Rx. Intravitreal Clindamycin brings dramatic improvement. The patients will continue oral treatment outlined above as well.

---

11. **What are the limitations of intravitreal anti toxoplasma therapy that you consider if any? How do you think we can overcome them in real-time practice?**

---

➤ **Dr. John A. Gonzales**

A limitation is the need for possibly frequent injections. More importantly, however, is the lack of any significant evidence that shows that intravitreal therapy is superior to systemic therapy.

---

➤ **Dr. Rupesh Agrawal**

Not widely used, no randomised controlled trial.

---

➤ **Dr. Daniel Vitor Vasconcelos-Santos**

Repeated injections may be needed, particularly in more severe cases. In addition, titration of local/systemic corticosteroids is not easy in this context, because of short half-life of clindamycin, with risk of steroid being unopposed by antibiotic.

---

➤ **Dr. Padmamalini M**

In cases of increased intraocular pressure or ocular surface infections we prefer to avoid intravitreal injections. Intravitreal antitoxo treatment alone is not sufficient enough to treat patients with associated systemic toxoplasmosis or in cases of congenital toxoplasmosis. Choose the appropriate systemic antitoxoplasma drugs to treat the condition.

---

➤ **Dr. Mamta Agarwal**

Limitations – More expensive as patient needs to be taken to OR for giving intravitreal injections. Also risk of complications like endophthalmitis, vitreous hemorrhage, retinal detachment etc. repeated injections may be needed for complete resolution.

Intravitreal injections are usually safe and I believe that we need to communicate and explain to our patients the advantages that an intravitreal injection affords to us. So a good communication with the patients is the key to overcoming the challenges faced in this scenario. Also taking all the sterile precautions while giving the injection is absolutely mandatory.

---

➤ **Avinash Pathengay**

When the patient needs more than one injection of intravitreal medication How to overcome: Discussion with the patient

---

➤ **Dr. B Manohar Babu**

Repeated intravitreal injections carry the risk of- endophthalmitis, RD, ocular hypertension/glaucoma, cataract, floaters and subconjunctival haemorrhage. Hence intravitreal anti toxoplasma therapy should be reserved for those who cannot tolerate oral therapy- allergy to sulpha, acid peptic disease, pregnancy, and severe progressive disease

---

## 12. Ocular Toxoplasma in immunosuppressed: How elegantly you suspect and tackle it?

---

### ➤ Dr. John A. Gonzales

Immunosuppressed individuals suspected of having an infectious process will receive an anterior chamber paracentesis. Depending on the clinical features, such patients may be immediately started on anti-toxoplasmosis therapy prior to return of the results from directed PCR.

---

### ➤ Dr. Rupesh Agrawal

I have a high index of suspicion if there are multifocal lesions and I will go with anti-toxoplasma therapy while treating his immunosuppressive status.

---

### ➤ Dr. Daniel Vitor Vasconcelos-Santos

Ocular toxoplasmosis may present with atypical and more severe clinical features in immunosuppressed patients. Please see above response to question no. 8.

---

### ➤ Dr. Padmamalini M

We do not get classical presentation in immunosuppressed cases. We have atypical presentations larger lesions without vitreous reaction and CNS involvement gives us a clue to diagnose toxoplasmosis in immunosuppressed individuals. Most of the patients, we treat them with antitoxo treatment using Trimethoprim + Sulfamethaxazole twice a day. In immunosuppressed individuals not responding to BD dose of Trimethoprim + Sulfamethaxazole, we increase the dose of the drug to CNS toxoplasmosis treatment regimen if there is associated CNS involvement.

---

### ➤ Dr. Mamta Agarwal

Ocular Toxoplasma in immunosuppressed patients including HIV patients, transplant recipients and lymphoma patients may be caused by reactivation of chronic infection or a newly acquired infection. It may also involve central nervous system presenting as diffuse neurological dysfunction as seizures or focal deficits due to encephalopathy, meningoencephalitis. Pneumonitis, myocarditis and multiple organ failure may also develop. Ocular toxoplasmosis in AIDS occurs in 1-3% cases. Ocular lesions may be bilateral, multifocal or large confluent areas of retinal necrosis usually not adjacent to old retinochoroidal scars but perivascular in distribution. May also mimic CMV retinitis, syphilitic retinitis, progressive outer retinal necrosis.

---

### ➤ Avinash Pathengay

I suspect when there are large lesions, multifocal involvement and absence of haemorrhages

---

### ➤ Dr. B Manohar Babu

This group of patients definitely need aggressive systemic (oral) anti-toxo treatment with or without intravitreal Clindamycin/ Dexamethasone. Many of these patients are also likely to be on Pneumocystosis prophylaxis (Tab. Bactrim) as well, need to continue to prevent relapse and dissemination of the infection. Avoid Pyrimethamine (bone marrow suppression).

---

### 13. Ocular Toxoplasma in an infant: How carefully you deal it?

---

➤ **Dr. John A. Gonzales**

I have not personally seen a case of toxoplasmosis in an infant. However, I believe a suggested therapeutic option would include pyrimethamine, sulfadiazine, and folinic acid.

---

➤ **Dr. Rupesh Agrawal**

I do not have any experience of managing ocular toxoplasma in infant.

---

➤ **Dr. Daniel Vitor Vasconcelos-Santos**

Because of immunoimmaturity of babies and increased severity of congenital toxoplasmosis in this age group, treatment should be maintained during the whole first year of life. The treatment of first choice is combination of sulfadiazine, pyrimethamine and folinic acid, supplemented with corticosteroids in cases of involvement of macula, optic disc or concomitant meningoencephalitis.

---

➤ **Dr. Padmamalini M**

In infants, I have treated them with antitoxoplasma treatment (Trimethoprim + Sulfamethaxazole) for one year. During acute presentation which is vision threatening i have treated with short course of oral corticosteroids along with antitoxoplasma treatment we treat for one year with antitoxoplasma treatment .

---

➤ **Dr. Mamta Agarwal**

I do not have an experience of treating an active lesion in an infant . All inactive congenital scars lead to amblyopia or decreased vision. In infants, a complete systemic evaluation in conjunction with a paediatrician is needed. Apart from that systemic treatment should b e started in co-ordinating with the paediatrician.

---

➤ **Avinash Pathengay**

I have not seen one, would send to paediatrician

---

➤ **Dr. B Manohar Babu**

Newborns and infants with congenital ocular toxoplasmosis should receive treatment within the first year of life with a combination of pyrimethamine, sulfadiazine and folinic acid (Soheilian 2011).

---

## 14. Ocular Toxoplasma in a pregnant mother. How do you approach in your practice?

---

### ➤ Dr. John A. Gonzales

Similar to infants, I have not dealt with ocular toxoplasmosis in pregnant women. However, options include azithromycin, clindamycin, or atovaqone. Sulfonamides may be used during the first two trimesters. No sulfonamides should be used at the last trimester due to a risk of kernicterus in the newborn. Spiramycin has also been used in pregnant women and has special approval in the US as an orphan drug. Pyrimethamine is teratogenic and is avoided during the first trimester.

---

### ➤ Dr. Rupesh Agrawal

I will be discussing with Obstetrician and start the treatment based on the location of the lesion and if it is vision threatening or not. I will do counselling to the family for chances of baby having toxoplasma. We do not have good pregnancy education program, which is there in some countries and particularly France – we need to adopt such a program for pregnant female for prevention against toxoplasma.

---

### ➤ Dr. Daniel Vitor Vasconcelos-Santos

Pregnant women with primary toxoplasmic retinochoroiditis associated with recently acquired infection should be invariably treated to prevent transplacental transmission. In cases of localized retinal reactivation in women with chronic infection, treatment depends on severity. Small lesions may be initially followed. Large and/or progressive lesions threatening the central retina should be treated, with the caution to avoid pyrimethamine in the first trimester (as it is potentially teratogenic) and sulfadiazine in the last few weeks (because of risk of kernicterus). Intravitreal therapy may be an option for these recurrences during pregnancy.

---

### ➤ Dr. Padmamalini M

I prefer to order serological test for toxoplasmosis Ig M antibody , Ig G antibody and Ig G avidity test. Pregnant women with recurrent ocular disease can be reassured that vertical transmission is a rare event. Antitoxoplasma treatment in an immunocompetent pregnant women with previous infection with toxoplasmosis, treatment is not indicated. If acute infection is suspected, patient should be started spiramycin immediately and repeat serological titers are done after 2-3 weeks. If fetal infection has been confirmed then I prefer to treat the patient with combination of pyrimethamine, sulfadiazine, and folinic acid . In this I will avoid pyrimethamine in first trimester and sulphadiazine in third trimester of pregnancy. Intravitreal clindamycin can also be used to treat intraocular toxoplasmosis in pregnancy

---

### ➤ Dr. Mamta Agarwal

Intravitreal clindamycin

---

### ➤ Avinash Pathengay

Intravitreal clindamycin, send to obstetrician

---

My Approach-

SCENARIO A. Ocular Toxoplasmosis- Recurrent, in a pregnant woman in her 1st trimester with serology results-

Toxo IgM- Negative, Toxo IgG- Positive

Treatment for retinitis-

-If Pregnancy < 16 weeks- Azithromycin or Clindamycin.

-If Pregnancy > 16 weeks- Azithromycin or Clindamycin or Trimethoprim/Sulphamethoxazole (TMP/SMX).

No risk to fetus as infection in mother acquired before conception

SCENARIO B. Ocular Toxoplasmosis- first episode in a pregnant woman in her 1st trimester with serology results-

Toxo IgM-

PositiveToxo

IgG- Positive or a fourfold increase seen

IgG avidity- low

Treatment- For retinitis-

-If Pregnancy < 16 weeks- Azithromycin or Clindamycin

-If Pregnancy > 16 weeks- Azithromycin or Clindamycin or TMP/SMX

Risk to fetus + as infection in mother acquired just before or during pregnancy

---



15. Preventing toxoplasma transmission from mother to child # [Not equal to] Treating ocular Toxoplasma in a pregnant mother> do you agree? If so please illustrate the treatment options.

---

➤ **Dr. John A. Gonzales**

Vertical transmission from mother to baby during recurrent ocular toxoplasmosis (as opposed to acute, primary infection in the mother) is rare, so there is nothing in particular that I would do in terms of therapy to prevent transmission. Rather, treatment would be instituted if the mother had active ocular toxoplasmosis

---

➤ **Dr. Rupesh Agrawal**

France has a very unique program and we need to look at that and use that globally.

---

➤ **Dr. Daniel Vitor Vasconcelos-Santos**

I agree. Please see above response to question no. 14.

---

➤ **Dr. Padmamalini M**

Yes they are different. I prefer to start the pregnant mother with ocular toxoplasmosis with oral spiramycin and continue the treatment throughout the pregnancy to prevent the transmission to the child and treatment of ocular toxoplasmosis in pregnant ladies includes pyrimethamine, sulfadiazine, and folic acid

---

➤ **Dr. Mamta Agarwal**

During pregnancy, prenatal antibiotic therapy for toxoplasmosis infection has no impact on fetomaternal transmission rate but it reduces the severity of disease in infected infants.

---

➤ **Avinash Pathengay**

I don't treat pregnant females , refer it to her Obstetrician.

---

➤ **Dr. B Manohar Babu**

AS DESCRIBED IN SCENARIO B- Risk to fetus + if infection in mother acquired just before or during pregnancy- IgM/IgG positive

-Treatment-

Maternal –Spiramycin- 1g oral 8th hourly for the total duration of pregnancy to prevent vertical transmission

-If fetal infection confirmed(+ve PCR in amniotic fluid/USG findings of hydrocephaly,hepatosplenomegaly)- add Pyrimethamine and Sulphadiazine or TMP/SMX from 16th week

---

16. Do you do CNS imaging for Toxoplasma in special situations? If so how does it changes your treatment plan?

---

➤ **Dr. John A. Gonzales**

If there is an optic neuropathy (manifesting as significantly reduced vision out of proportion to clinical exam or an afferent pupillary defect) I may consider CNS imaging

---

➤ **Dr. Rupesh Agrawal**

If there are any CNS symptoms, we can consider neuroimaging. The treatment once again will be in close consultation with neurologist and will be admission and more aggressive antitoxoplasma treatment.

---

➤ **Dr. Daniel Vitor Vasconcelos-Santos**

CNS imaging is indicated in congenital toxoplasmosis and in severely immunosuppressed patients (e.g. HIV coinfection).

---

➤ **Dr. Padmamalini M**

Yes in selected cases like congenital toxoplasmosis and in immunodeficient states. If there is associated CNS involvement we treat with CNS antitoxoplasma treatment regimen.

---

➤ **Dr. Mamta Agarwal**

Imaging is done only in immunosuppressed patients especially HIV patients

---

➤ **Avinash Pathengay**

I don't do unless the pt has CNS symptoms

---

➤ **Dr. B Manohar Babu**

Not done till date

---

17. Do you observe active Toxoplasma lesions if it does not involve papillomacular bundles and in the periphery with no disturbance in the vision parameters? Or do you still treat them as well in the concern to tackle recurrences?

---

➤ **Dr. John A. Gonzales**

I have, on rare occasion, monitored peripheral lesions when they have been in the periphery and the vision has been unaffected (aside from perhaps minor floaters experience by the patient). I explain to each patient that there is not necessarily any one treatment that is superior to another and for peripheral lesions one option is to closely monitor without treatment. In some cases, some patients have opted to monitor without treatment. I would still treat even for a peripheral lesion if the patient had some sort of primary or secondary immunodeficiency.

---

➤ **Dr. Rupesh Agrawal**

I will treat them.

---

➤ **Dr. Daniel Vitor Vasconcelos-Santos**

I usually treat, unless the lesion is very small, peripheral and resolving.

---

➤ **Dr. Padmamalini M**

I prefer to treat these cases.

---

➤ **Dr. Mamta Agarwal**

I treat all active toxoplasmic retinochoroiditis lesions because they produce tachyzoites that spread to distant areas of retina and encyst. Treatment reduces tachyzoites by inhibiting the multiplication of the parasite and thus risk of recurrences. Also active lesions may be associated with macular edema, tractions, severe vitritis and retinal detachment which needs treatment.

---

➤ **Avinash Pathengay**

Observe if the patient is asymptomatic, serial photographic documentation. No need of Rx.

---

➤ **Dr. B Manohar Babu**

Yes, I will treat. Though defined as a self-limiting retinitis, it can still cause intraocular inflammation leading to changes in the vitreous humor (floaters) and untreated toxoplasma retinitis has been shown to recur more often than in those who have been treated. Lesions in the periphery tend to be large and take a longer time to heal

---

## 18. What do you do differently in a case of "too often recurring proven toxoplasma"?

---

### ➤ Dr. John A. Gonzales

I will examine for an underlying primary or secondary immunodeficiency. Additionally, I will consider longer-term therapy with intermittent trimethoprim-sulfamethoxazole (every 3 days).

---

### ➤ Dr. Rupesh Agrawal

Reconsider my diagnosis and keep them on long term maintenance therapy.

---

### ➤ Dr. Daniel Vitor Vasconcelos-Santos

I start prophylactic treatment with sulfamethoxazole/trimethoprim 3x/week or every other day.

---

### ➤ Dr. Padmamalini M

I prefer to start the patient on long term anti toxoplasma prophylaxis treatment.

---

### ➤ Dr. Mamta Agarwal

I have not really come across too often recurring toxoplasma lesion. However, chronic toxoplasmic retinochoroiditis can be seen when active lesions persists more than 3 months. In these cases, antitoxoplasmic treatment can be continued till complete resolution. Corticosteroid is also added to control inflammation and reduce the complications like macular edema, vitritis and vasculitis.

---

### ➤ Avinash Pathengay

Keep the pt on maintenance dose, fortunately its very rare in India.

---

### ➤ Dr. B Manohar Babu

-Use of systemic steroids without antibiotics and subconjunctival injection of steroids were identified as the main factors related to recurrence (A De La Torre 2009).

- In a double-masked randomized placebo controlled study- Patients were treated for active toxoplasma retinochoroiditis with trimethoprim-sulfamethoxazole (160 mg–800 mg) for 45 days. Ninety five patients were randomized 1: 1 to treatment with either trimethoprim-sulfamethoxazole or placebo every 2 days. By 12 months there had been no recurrences in the treatment group, while recurrence was noted in 12.8% of patients in the placebo group (Felix et al 2014).

---

## 19. How do you rule out the differentials of toxoplasma in a case of monofocal retinitis with and without significant vitritis?

---

### ➤ Dr. John A. Gonzales

If there is a diagnostic dilemma and there is a lack of certainty as to toxoplasmosis or other entity, consideration can be made for anterior chamber or vitreous paracentesis with directed PCR sent for toxoplasma and herpetic viruses. Alternatively, if there is a poor view and other entities are on the differential (such as vitreoretinal lymphoma), then a diagnostic and therapeutic vitrectomy with appropriate microbiologic and cytopathologic/flow cytometric processing. Additionally, at the Proctor Foundation/UCSF we use in-house metagenomic deep sequencing to identify any pathogen that may be present in the ocular specimen. This has revolutionized how we treat and manage infectious uveitis. A limitation of directed PCR is that one must “know what one is looking for.” If there is a pathogen in the specimen that one may not have considered or perhaps routine PCR does not exist for that pathogen, it will be missed on directed PCR. Metagenomic deep sequencing sequences all genomic material in a specimen in an unbiased fashion and is able to detect any infectious pathogen if it is present in the sample.

---

### ➤ Dr. Rupesh Agrawal

Clinical lesions, AC tap and other blood investigations.

---

### ➤ Dr. Daniel Vitor Vasconcelos-Santos

Please see above response to question no. 8.

---

### ➤ Dr. Padmamalini M

Monofocal retinitis without vitritis I prefer to rule out immunodeficiency conditions. Monofocal retinitis with vitritis, differentials include syphilitic retinitis, viral retinitis, fungal retinitis and post fever retinitis. Based on the associated systemic and ocular features along with serology and molecular diagnostic reports, I prefer to differentiate these entities.

---

### ➤ Dr. Mamta Agarwal

- Differential diagnosis :
  - PCR (Aqueous / vitreous) – HSV, VZV, CMV, Panfungal, bacteria
  - Mantoux test, RPR, TPH
- 

### ➤ Avinash Pathengay

Retinitis in toxo is generally 1-1/2 DD in size; anything bigger than that -suspect differentials like Viral ( Herpetic group), Bacterial ( Cat scratch) , candida Retinitis . To rule out---VitBx

---

### ➤ Dr. B Manohar Babu

In a media with no view of the fundus- I would suspect Endogenous Endophthalmitis and Acute Retinal Necrosis.

Other differentials are- necrotizing retinitis due to CMV, herpes simplex virus, herpes zoster virus, fungal retinitis (candidiasis, blastomycosis), septic retinitis, ocular toxocariasis, sarcoidosis, syphilis and tuberculosis are other diagnoses to exclude when considering toxoplasmosis. Punctate outer retinal toxoplasmosis is an atypical form of ocular toxoplasmosis that may be confused with other white dot syndromes (Soheilian 2011).

---

20. **Polymerase chain reaction for Toxoplasma: How often you do? Please illuminate us on the specific indications and the nuances to co-relate the lab reports? When do you consider false positive, false negative PCR reports?**

---

➤ **Dr. John A. Gonzales**

We perform an anterior chamber paracentesis on nearly every patient with suspected infectious uveitis. Thus, nearly every patient (unless they refuser) has directed PCR performed typically for toxoplasma, HSV, VZV, and CMV. If there is a strong clinical suspicion for toxoplasma, but PCR is negative, a false positive is considered particularly if serologic assay indicates past exposure to toxoplasma (positive serum IgG).

---

➤ **Dr. Rupesh Agrawal**

Polymerase chain reaction for Toxoplasma: How often you do? Please illuminate us on the specific indications and the nuances to co-relate the lab reports? When do you consider false positive, false negative PCR reports?

We perform an anterior chamber paracentesis on nearly every patient with suspected infectious uveitis. Thus, nearly every patient (unless they refuser) has directed PCR performed typically for toxoplasma, HSV, VZV, and CMV. If there is a strong clinical suspicion for toxoplasma, but PCR is negative, a false positive is considered particularly if serologic assay indicates past exposure to toxoplasma (positive serum IgG).

---

➤ **Dr. Daniel Vitor Vasconcelos-Santo**

The main indication for PCR in my view is atypical toxoplasmosis (please see above response to question no. 8). With a reliable lab, false positives are rare. However, sensitivity of PCR of aqueous humor for toxo is relatively low, between 30-50%, depending on the degree of AC involvement and on the immune status. In other words, a positive PCR result confirms, but a negative result does not rule-out toxoplasmosis. In contrast, sensitivity of PCR for herpesviruses is quite high, being useful to confirm (and even to almost rule-out) this etiology in the context of atypical presentation.

---

➤ **Dr. Padmamalini M**

I do it in atypical cases and not routinely. In atypical cases or immunocompromised cases or associated with multiple systemic diseases with compromised renal functions I prefer to do the PCR to confirm the diagnosis. When I get multiple organisms are positive by PCR then I prefer to consider the possibility of false positive report. In typical cases with strongly positive serological tests with negative PCR, I prefer to consider false negative PCR.

---

➤ **Dr. Mamta Agarwal**

PCR test from aqueous or vitreous fluid is usually done in atypical retinochoroiditis lesions which do not respond to standard antitoxoplasmic therapy. Also in cases with co infections like syphilis, tuberculosis in immunosuppressed patients, PCR can be helpful. However clinical co relation is necessary in cases of false positive and negative results.

---

➤ **Avinash Pathengay**

I don't do PCR

---

➤ **Dr. B Manohar Babu**

How often do I do PCR- mentioned in answers above. Not often, when fundus exam is not possible in dense vitritis or atypical lesions, aggressive clinical course, and poor response to Rx.

You can use/print this methodology if deemed important-

Procedure as done in AMRF-

PCR for Toxoplasma gondii- Target gene: B1 gene

Positive control: DNA obtained from AIIMS

Primer: I Round (Uniplex)

Forward : 5' TGC ATA GGT GTC AGT CAC TG 3'

Reverse : 5' GGC GAC CAA TCT GCG AAT ACA CC 3'

Amplification product: 193 bp

Primers: II Round (Nested)

Forward: 5' TGC ATA GGT TGC AGT CAC TG 3'

Reverse: 5' GGC GAC CAA TCT GCG AAT ACA CC 3'.

Amplification product: 96 bp

I round Amplification:

SEGMENT	TEMP °C	TIME min.	PURPOSE
1	94	3 min	Initial denaturation
2	94	30 sec	Cyclic denaturation
3	52	30 sec	Annealing of primers
4	72	30 sec	Synthesis of DNA

Total No. of cycles : 40

Final Extension : 72 o C for 5 minutes.

II round Amplification:

SEGMENT	TEMP °C	TIME min.	PURPOSE
1	94	2 min	Initial denaturation
2	94	10sec	Cyclic denaturation
3	55	10sec	Annealing of primers
4	72	15 sec	Synthesis of DNA

Total No. of cycles : 39

Final Extension : 72 o C for 5 minutes

21. **In a real time scenario of active as well as healed toxoplasma with cystoid macular edema:  
How do you manage in your clinic?**

---

➤ **Dr. John A. Gonzales**

I would manage with systemic therapy and depending on the level of vitritis, first manage the macular edema with either topical corticosteroids (we have difluprednate 0.05% in the US) or with systemic corticosteroids (after systemic antimicrobials have commenced).

---

➤ **Dr. Rupesh Agrawal**

Topical and systemic steroids, periocular steroids.

---

➤ **Dr. Daniel Vitor Vasconcelos-Santos**

Usually CME subsides to corticosteroids in addition to antiparasitic drugs for treatment of active retinochoroiditis. Healed lesions are not associated with CME, unless CNV or ERM is present.

---

➤ **Dr. Padmamalini M**

In active toxoplasmosis cases, I prefer to treat them with systemic antitoxoplasma therapy with oral steroids. In healed toxo cases if there is CME I prefer to do OCT to rule out underlying pathologies like CNVM, then I prefer to treat the inactive cases with anti VEGF therapy.

---

➤ **Dr. Mamta Agarwal**

In active lesion with cystoid macular edema, oral steroid and topical NSAIDS can be added. Local corticosteroid in the form of periocular and intravitreal injection must be avoided. However in completely healed inactive lesion, periocular triamcinolone acetonide injection can be helpful.

---

➤ **Avinash Pathengay**

CME in active Toxo resolves with infection, they are usually not chronic. I have not come across CME post resolution of infection though it can occur if there occurs tractional maculopathy

---

➤ **Dr. B Manohar Babu**

Treat each as separate entities, I should avoid intravitreal Tricort for macula edema

---



22. **In a real time scenario of active as well as healed toxoplasma with choroidal neovascular membrane: How do you manage in your clinic?**

---

➤ **Dr. John A. Gonzales**

I would manage with systemic antimicrobials, systemic corticosteroids (after antimicrobials have commenced) because I am concerned that an inflammatory component is helping to drive the CNVM. Additionally, intravitreal anti-VEGF therapy would be ideal.

---

➤ **Dr. Rupesh Agrawal**

Intra vitreal anti VEGF agents.

---

➤ **Dr. Daniel Vitor Vasconcelos-Santos**

I usually treat the patient with systemic antiparasitic drugs and corticosteroids, in addition to intravitreal anti-VEGF therapy.

---

➤ **Dr. Padmamalini M**

In active toxoplasmosis cases with choroidal neovascular membrane: , I prefer to treat them with antitoxo , oral steroids and anti VEGF agents. In healed toxoplasma with choroidal neovascular membrane: I prefer to treat them with anti VEGF agents.

---

➤ **Dr. Mamta Agarwal**

Active lesion with choroidal neovascular membrane, oral steroid , topical NSAIDS and Intravitreal anti VEGF can be added along with anti toxoplasmic therapy. However in completely healed inactive lesion, intravitreal anti VEGF can be helpful.

---

➤ **Avinash Pathengay**

When active Both anti VEGF and Tab Bactrim DS When healed: Anti-VEGF

---

➤ **Dr. B Manohar Babu**

Treat each as separate entities.

---

23. **In a real time scenario of active as well as healed toxoplasma with visually significant complicated cataract: How do you manage in your clinic?**

---

➤ **Dr. John A. Gonzales**

It would be important to have quiescence of that active lesion so that the patient could proceed with cataract surgery. In such a case, I would treat with antimicrobials and systemic corticosteroids. I would highly recommend that the patient's inflammation/infection be inactive for at least three months before proceeding with surgery. Additionally, I would start prophylactic antimicrobial therapy before the planned surgery and continue afterwards. The patient would be discontinued after therapy after ensuring that there was no recrudescence of infection or inflammation following surgery

---

➤ **Dr. Rupesh Agrawal**

After toxo lesion is healed, to operate on cataract, if active lesions – to treat them first.

---

➤ **Dr. Daniel Vitor Vasconcelos-Santos**

In the present of active disease, I first treat and proceed to surgery a few months later. When it is healed, surgery may be indicated.

---

➤ **Dr. Padmamalini M**

I prefer to wait for the inflammation to become inactive and then take the case for cataract surgery under antitoxoplasma prophylaxis cover. Inactive cases I prefer to operate under antitoxoplasma prophylaxis cover.

---

➤ **Dr. Mamta Agarwal**

Active toxoplasmic retinochoroiditis is treated completely before cataract surgery is done. I do not give prophylactic anti toxo treatment whenever cataract surgery is performed.

---

➤ **Avinash Pathengay**

Healed lesion--Phaco IOL, if active- Treat the toxo and opt for cataract surgery later

---

➤ **Dr. B Manohar Babu**

- In a quiet healed eye with cataract- I just do a phacoemulsification with IOL implantation in in the bag.  
- In an inflamed eye with visible active retinitis and cataract- I will treat the retinitis and inflammation before surgery.

In an eye with suspected ocular toxoplasmosis- with no view of the fundus due to either a cataract or dense vitritis- a combination of procedures (cataract surgery, vitrectomy) may be attempted under anti- toxoplasma treatment and oral steroid cover.

---

24. In a real time scenario of active as well as healed toxoplasma with glaucoma ,uncontrolled with maximum medical therapy for intraocular pressure : How do you manage in your clinic?

---

➤ **Dr. John A. Gonzales**

I would recommend starting antimicrobial therapy before surgery and continuing afterwards.

---

➤ **Dr. Rupesh Agrawal**

Never encountered this.

---

➤ **Dr. Daniel Vitor Vasconcelos-Santos**

Secondary ocular hypertension associated with active ocular toxoplasmosis typically subsides to systemic / topical treatment. In the presence of uncontrolled glaucoma, I first treat the infection and then proceed to anti-glaucoma surgery.

---

➤ **Dr. Padmamalini M**

In cases of Healed toxoplasmosis , uncontrolled with maximum medical therapy I prefer to go for surgical management such as trabeculectomy or Tube implant antiglaucoma surgery. In active cases, I prefer to continue the medical management with antitoxoplasma, systemic steroids with continuation of antiglaucoma medications with closely monitoring of IOP and inflammation. If the patient is steroid responder then I prefer to taper and stop the steroids or change to less potent steroids. In spite of all our efforts if the IOP is continue to be high, surgical management with trabeculectomy or tube implant can be done under guarded visual prognosis after explaining the complications and the disease course.

---

➤ **Dr. Mamta Agarwal**

With uncontrolled intraocular pressure , on maximum medical therapy in a patient with active or healed lesion, filtering surgery is required

---

➤ **Avinash Pathengay**

I have not come across a case of uncontrolled glaucoma in toxoplasmosis. if I do, I would take glaucoma consultation

---

➤ **Dr. B Manohar Babu**

In healed ocular toxoplasmosis, glaucoma can be treated as per SOP for glaucoma Rx. In active ocular toxoplasmosis- topical and oral corticosteroids are to be used with caution under anti-glaucoma medication cover

---

25. Do you follow in your practice, prophylactic therapy for toxoplasma therapy in an attempt to avoid recurrences?

---

➤ **Dr. John A. Gonzales**

Yes, particularly for ocular surgical procedures.

---

➤ **Dr. Rupesh Agrawal**

Yes, I do in some patients.

---

➤ **Dr. Daniel Vitor Vasconcelos-Santos**

Yes, please see above reponse to question no. 18.

---

➤ **Dr. Padmamalini M**

Yes in high risk cases and also patient who is on systemic immunosuppressive therapy for systemic autoimmune diseases, I prefer to give them long term antitoxoplasma prophylaxis therapy.

---

➤ **Dr. Mamta Agarwal**

I do not give prophylactic therapy for toxoplasma.

---

➤ **Avinash Pathengay**

Yes in immunocompromised patients

---

➤ **Dr. B Manohar Babu**

I see recurrences in my patients few and far in between- recurrences 6 months apart- I prefer to treat them with 6 weeks of conventional therapy in case of reactivation.

Yes, there was one patient-once the recurrent lesion was quiet, I prescribed oral Bactrim DS once daily once in 3 days for 3 months- but the lesion recurred and she lost faith in my treatment

---

## 26. Diagnostic challenge:1

	Immunoglobulin M Positive	Immunoglobulin M Negative
Immunoglobulin G Positive	Situation A	Situation B
Immunoglobulin G Negative	Situation C	Situation D

Please tell us what do you do in situations A, B, C, D respectively?

---

### ➤ Dr. John A. Gonzales

Situation A = treat with antimicrobials/steroids

Situation B = treat with antimicrobials/steroids

Situation C = treat with antimicrobials/steroids

Situation D = consider another paracentesis (if has not been done already) to evaluate for toxoplasma again as well as other pathogens by directed PCR. Recheck serum IgM and IgG in three weeks.

---

### ➤ Dr. Daniel Vitor Vasconcelos-Santos

In the presence of active retinochoroiditis:

A: Treat

B: Treat

C: Likely false positive. Treat only if IgM with high titers and repeated serology with low avidity IgG

D: Very unlikely toxoplasmosis.

In the absence of retinochoroiditis, I only treat immunosuppressed or symptomatic patients.

---

### ➤ Dr. Padmamalini M

A. Active infection

B. Active Infection

C. Active infection

D. No infection

I prefer to correlate the lab investigational reports with the clinical features and then decide about the management

---

### ➤ Dr. Mamta Agarwal

Diagnosis is indeed done clinically & serological tests just confirm the diagnosis.

A – IgG & IgM +ve – Treat

B- IgG +ve & IgM -ve – Treat based on clinical suspicion

C- IgG -ve & IgM +ve – Treat based on clinical suspicion

D- IgG & IgM -ve – Treat only if clinical diagnosis is certain otherwise will rule out other causes of retinochoroiditis

---

---

➤ **Dr. B Manohar Babu**

A. Patient with acute acquired toxoplasmosis- treat the ocular lesion.

B. Seropositive patient- observe if no active ocular lesions, treat if any active ocular lesions (4 fold rise of IgG signifies recent reactivation).

C. Patient with acute acquired toxoplasmosis- treat the ocular lesion, if no ocular lesion is present- rule out false positive IgM test (False-positive IgM can be caused by autoimmune antibodies including rheumatoid factor and antinuclear antibodies, acute viral infection, and non-specific in vitro binding.)

D. Relax-if no ocular lesion, if clinical suspicion of ocular toxoplasmosis- treat and repeat IgM/IgG a week later/acquire vitreous samples for histology, PCR.

IgG appear in 1-2 weeks after infection, peak at 1-2 months, then fall- but remain detectable for life.

IgM appear in 1-2 weeks after infection, persist upto 1 year at low titers before becoming undetectable. Does not cross the placenta.

---

## 27. Diagnostic Challenge:2

	PCR Toxoplasma positive	PCR Toxoplasma negative
Either Toxoplasma serology positive	Situation A	Situation B
Either Toxoplasma serology negative	Situation C	Situation D

**Please tell us what do you do in situations A, B, C, D respectively?**

### ➤ Dr. John A. Gonzales

Situation A = treat with antimicrobials

Situation B = treat with antimicrobials

Situation C = treat with antimicrobials

Situation D = treat with antimicrobials

If PCR for toxoplasma was negative and BOTH serologies were negative, I would make consideration for another disease entity or masquerade. Consideration could also be made for early toxoplasma infection (particularly if the lesion was otherwise classic for toxoplasma) and rechecking serologies could be performed three weeks later.

### ➤ Dr. Daniel Vitor Vasconcelos-Santos

In the presence of active retinochoroiditis:

A: Treat

B: Treat

C: Likely false positive PCR if negative IgG. Treat only if IgG is present.

D: Very unlikely toxoplasmosis.

### ➤ Dr. Padmamalini M

A. Active infection

B. Active Infection

C. Active infection

D. No infection

I prefer to correlate the lab investigational reports with the clinical features and then decide about the management

### ➤ Dr. Mamta Agarwal

	PCR Toxoplasma positive	PCR Toxoplasma negative
Either Toxoplasma serology positive	Situation A Treat	Situation B Treat
Either Toxoplasma serology negative	Situation C Treat	Situation D Do not treat

### ➤ Avinash Pathengay

I do not practise PCR

### ➤ Dr. B Manohar Babu

A. Treat.

B. Treat.

C. Treat if clinical suspicion of active ocular toxoplasmosis.

D. See response for D in previous question.

28. Do you consider to do PCR from aqueous or vitreous sample? How do you explain the variations in the results from the same patient?

---

➤ **Dr. John A. Gonzales**

Directed PCR requires that there is sufficient pathogen at the assay's level of detection. Thus, it is possible that a patient may have ocular toxoplasmosis, but if at the time that the paracentesis is performed, there is pathogen below the level of detection for the assay, the test will result as negative. Clinical correlation/interpretation is always required.

---

➤ **Dr. Rupesh Agrawal**

Aqueous.

---

➤ **Dr. Daniel Vitor Vasconcelos-Santos**

Sensitivity of toxoplasma PCR of vitreous is significantly higher than of aqueous humor, because of predominant parasitic load in the posterior segment. Immunosuppressed patients, however, may have infection of the anterior segment as well.

---

➤ **Dr. Padmamalini M**

I prefer to do it from aqueous if there is anterior segment inflammation. If the patient is undergoing PPV or diagnostic vitrectomy then I do it from the vitreous sample. From the vitreous it is more sensitive than aqueous in cases of retinochoroiditis due to toxoplasmosis.

---

➤ **Dr. Mamta Agarwal**

PCR from aqueous and vitreous is done in atypical lesions or if there is dense vitreous inflammation which obscures the clinical diagnosis.

---

➤ **Avinash Pathengay**

I do not practise PCR

---

➤ **Dr. B Manohar Babu**

In one patient have repeated intravitreal Clindamycin once.

---

➤ **Dr. B Manohar Babu**

Montoya and associates (1999) stated a preference for vitreous testing in toxoplasmic chorioretinitis because of the large size of the organism.

In patients with large lesions >3DD, immunocompromised individuals yield (positivity) higher.

PCR in peripheral blood is currently used with immunocompromised patients for the diagnosis of cerebral (especially in HIV-positive patients) or disseminated toxoplasmosis.

In a study by Bourdin C et al (2004) PCR with ocular samples (Not mentioned from aqueous or vitreous) yield 35.9% sensitivity, while immunoblotting and calculation of the Goldmann-Witmer coefficient yield 47.6% and 72.3% sensitivities, respectively. Performing these three methods together provided 89.4% sensitivity

---



## 29. How often do you repeat the intravitreal anti-Toxoplasma therapy?

---

➤ **Dr. John A. Gonzales**

This is very case dependent. If there is persistent activity or if a patient cannot tolerate oral therapy, then repeated intravitreal therapy may be indicated.

---

➤ **Dr. Rupesh Agrawal**

Maximum thrice and after 72 hours.

---

➤ **Dr. Daniel Vitor Vasconcelos-Santos**

Weekly if needed.

---

➤ **Dr. Padmamalini M**

For intravitreal clindamycin I repeat after 72 hours.

---

➤ **Dr. Mamta Agarwal**

Intravitreal anti toxoplasma therapy can be repeated every 2 weeks till complete healing.

---

➤ **Avinash Pathengay**

5-7 days

---

➤ **Dr. B Manohar Babu**

In one patient have repeated intravitreal Clindamycin once

---

30. **Does the results of serological tests influence your choice of oral versus intravitreal therapy based on the recent Randomized Controlled Trial by Soheilian et al?**

---

➤ **Dr. John A. Gonzales**

The differences between the two groups as described in Soheilian et al. does not influence my choice of oral versus intravitreal therapy.

---

➤ **Dr. Rupesh Agrawal**

Nope.

---

➤ **Dr. Daniel Vitor Vasconcelos-Santos**

No. This was a very small trial, not designed to address this issue. In the setting of recently acquired toxoplasmosis, however, systemic therapy makes much more sense.

---

➤ **Dr. Padmamalini M**

No Ig M antibody positive cases , I prefer to treat them with systemic antitoxoplasma therapy whereas Ig M antibody negative cases to be treated with local therapy.

---

➤ **Dr. Mamta Agarwal**

No

---

➤ **Avinash Pathengay**

No I have specific indications for oral and intravitreal as described.

---

➤ **Dr. B Manohar Babu**

Did you mean the 2005 trial?

I have indicated my preference earlier. Pyrimethamine - in addition to its side effects is not freely available.

---

31. **What are the special situations you order for Toxoplasma avidity test? How do you interpret its findings in correlation with Toxoplasma Ig G and M test results?**

---

➤ **Dr. John A. Gonzales**

I have not ordered the toxoplasma avidity test

---

➤ **Dr. Daniel Vitor Vasconcelos-Santos**

When I suspect of recently acquired toxoplasmosis, low IgG avidity supports it.

---

➤ **Dr. Padmamalini M**

I order Toxoplasma avidity test in ocular toxoplasmosis with pregnancy or I want to find out the duration of infection or the IgG avidity test values are low in the early stage after primary infection, which was acquired within last 3 months .High toxoplasma IgG avidity values indicates that an infection likely occurred at least four months earlier.

---

➤ **Dr. Mamta Agarwal**

I do not do

---

➤ **Avinash Pathengay**

IgM in children – any titer is significant

IgM in adults - >1.64 indicates active infection

If IgMToxo positive – Oral Rx > Intravitreal Rx

IgG antibodies does not confirm the toxoplasmic aetiology

Negative IgG may generally discards the possibility

IgG appears in serum 1-2 weeks after infection – Detectable throughout lifetime

Rise in titer of IgG – Indication of recent infectio

---

➤ **Dr. B Manohar Babu**

The IgG avidity assay measures the strength of IgG binding to T gondii. In most cases IgG avidity shifts from a low to a high index about 5 months after the infection. Thus, patients with acute infection exhibit a low avidity index, suggesting that infection occurred within 5 months of testing, whereas those with previous infection have a high IgG avidity index

If IgM is positive indicating a recently acquired infection- there is no need for IgG avidity test.

If IgG is positive- IgG avidity test may be done.

---

### 32. **Toxoplasma suspect presenting as proven chorioretinitis rather than retinochoroiditis: How you approach differently?**

---

➤ **Dr. John A. Gonzales**

I'm not sure I understand the question. Is the question that there is a more choroidal involvement than a retinal involvement and whether this would affect my management? I would rule out other causes (namely syphilis and TB), but if my clinical suspicion was highest for toxoplasma, I would treat with anti-toxoplasma microbials

---

➤ **Dr. Rupesh Agrawal**

No differently.

---

➤ **Dr. Daniel Vitor Vasconcelos-Santos**

SD-OCT is very useful to clarify it. Toxoplasma leads to retinochoroiditis, but not chorioretinitis, as cysts are resident in the neurosensory retina (but not in the choroid).

---

➤ **Dr. Padmamalini M**

I prefer to get the OCT done and then treat the patient with systemic antitoxoplasma therapy with systemic steroids.

---

➤ **Dr. Mamta Agarwal**

Treatment still remains the same. However, OCT – ss and EDI –OCT can be done for follow up & Tubercular choroiditis & serpiginous choroiditis must also be kept in the differential diagnosis.

---

➤ **Avinash Pathengay**

The only way it presents as chorioretinitis when we have PORT lesions

---

➤ **Dr. B Manohar Babu**

Really? Ocular Toxoplasmosis is a retinitis with choroid involved secondarily, why do I have to approach differently. Kindly enlighten me.

---

### 33. **Toxoplasma presenting as endophthalmitis! Is it anyway approached/managed differently from the classical presentation of Toxoplasmosis?**

---

➤ **Dr. John A. Gonzales**

I would treat with systemic antimicrobials and would make consideration for an anterior chamber paracentesis if there was a question of whether there could be another etiology at play given the endophthalmitic appearance. In such a case I would also send for bacterial and fungal cultures. Additionally, since our center has metagenomic deep sequencing available, I would use that modality as well.

---

➤ **Dr. Rupesh Agrawal**

I will be more aggressive in my approach and admit the patient and start all the medications ASAP.

---

➤ **Dr. Daniel Vitor Vasconcelos-Santos**

No, even though differential diagnosis should include bacterial / fungal infection.

---

➤ **Dr. Padmamalini M**

Yes. We prefer to take this patients for intravitreal clindamycin or Parsplanavitrectomy earlier if they are not responding to systemic antitoxo treatment in endophthalmitis cases than classical toxoplasmosis presentation.

---

➤ **Dr. Mamta Agarwal**

A case of toxoplasmic endophthalmitis will need pars plana vitrectomy with intravitreal antitoxoplasmic therapy along with systemic treatment.

---

➤ **Avinash Pathengay**

I have not seen one

---

➤ **Dr. B Manohar Babu**

If a retinitis is visible and ocular toxoplasmosis is confirmed by serology as well- oral anti- toxoplasma treatment under oral steroid cover +/- media clearing vitrectomy.

If unable to view the fundus – treatment should be according to protocols for exogenous/endogenous endophthalmitis- with vitreous sampling for PCR and serology (ELISA) for Toxoplasma IgG/IgM

---

34. **Although, it may be a trivia, to a beginner what are the clinical and adjunct parameters to discretely say that the suspected lesion is resolving versus not resolving or fully resolved?**

---

➤ **Dr. John A. Gonzales**

A resolving lesion typically begins to show less retinal edema. Over time, an inactive lesion becomes flat and typically becomes more shallow compared to the surrounding uninvolved retina. Additionally, there may be pigmentary lesions that begin to arise. I like to perform OCT if the lesions are not too far in the periphery which will demonstrate nicely an active lesion as being edematous and, over time as it becomes increasingly inactive, resolution of edema and typically resulting in disorganized and scarred retina.

---

➤ **Dr. Rupesh Agrawal**

Granular Edges of the lesion and overlying vitreous haze – signs of activity.

---

➤ **Dr. Daniel Vitor Vasconcelos-Santos**

Resolving toxoplasmic lesions display decreased vitreal exudation, decreased choroidal thickening and also progressively sharpening borders, with decreasing circumjacent retinal edema.

---

➤ **Dr. Padmamalini M**

Decrease in vitritis, vitreous haze, pigmentation of the retinochoroiditis lesions are suggestive of resolving toxoplasmosis. Healed chorioretinal scars with disappearance of precipitates in the posterior vitreous cavity suggestive of resolved lesions. Non Resolving are characterised by the presence of posterior vitreous cells, vitreous membranes with active lesions in spite of adequate antitoxoplasma and systemic steroid therapy.

---

➤ **Dr. Mamta Agarwal**

Signs of clinical resolution of an active lesion includes decrease in the size of retinochoroiditis lesions, margins getting well defined, reducing vitreous haze, vasculitis and macular edema if any. Fully resolved lesions appear as a pigmented scar with no vitritis.

---

➤ **Avinash Pathengay**

- i. Margins of lesion getting circumscribed
  - ii. Resolution of Subretinal fluid
  - iii. Appearance of Hard exudates
- 

➤ **Dr. B Manohar Babu**

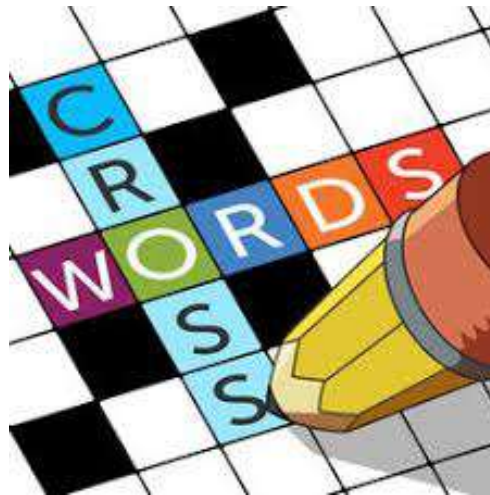Clinical judgement – sharp healed edges of the lesion with or without scarring, decreased vitritis (one should be able to differentiate between active and inactive vitritis), H/O completion of treatment protocol as advised. Serology is of limited value in following up a treated case to ascertain complete healing. (See response to question 26 on IgM/IgG persistence)

---



# The Perplexing Protozoa

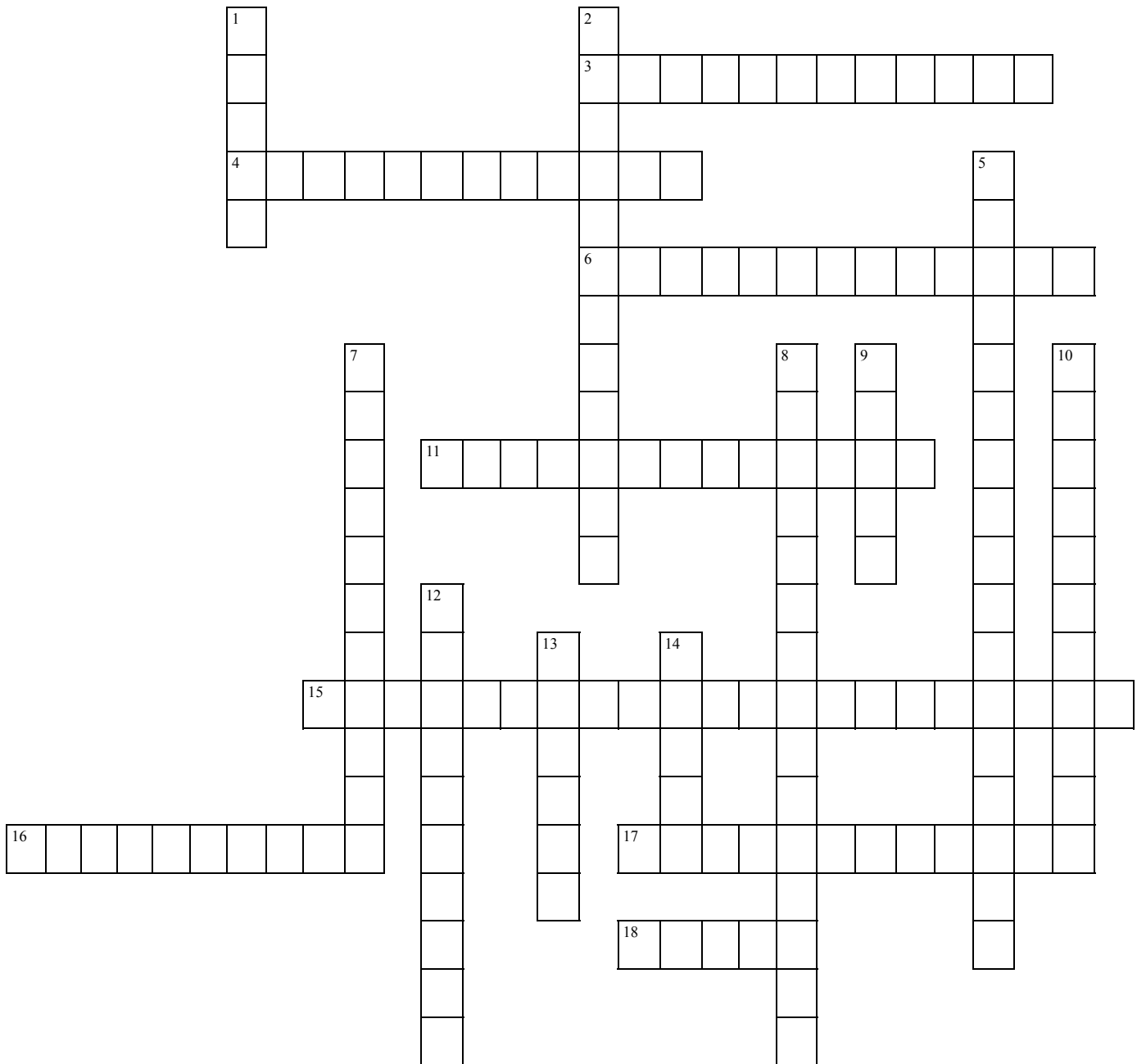
Dr. Vinaya Kumar Konana



# The Perplexing Protozoa

Dr. Vinaya Kumar Konana

Department of Uvea and Ocular Inflammation, Prabha Eye Clinic and Research Center  
Vittala International Institute of Ophthalmology





## Across

3. Anti-toxo drug that inhibits ribosomal protein synthesis
  4. Anti-toxo drug that inhibits paraaminobenzoic acid
  6. Name of the sign for tractional band connecting two toxo scars
  11. Anti-toxo drug that inhibits dihydrofolate reductase
  15. Exudates along the arterial wall seen in ocular toxoplasmosis
  16. Adjunctive therapy used with antifolate agents like pyrimethamine
  17. Most common manifestation of toxoplasmosis in patients with aids
  18. Trimester in which maternal infection can cause severe fetal disease
- 

## Down

1. Most common test used today for toxoplasmosis
2. Gold standard dye test for toxoplasmosis
5. Most common manifestation of congenital toxoplasmosis
7. Anti-toxo drug that causes pseudomembranous colitis
8. Most common systemic manifestation of acquired toxoplasmosis
9. Person who first described congenital toxoplasmosis with ocular involvement
10. Fastest replicating form of *Toxoplasma gondii*
12. Safest anti-toxo drug during pregnancy
13. Definitive host of *Toxoplasma gondii*
14. Tetrad of microcephaly, intracranial calcification, mental retardation and retinochoroiditis



# **An interesting case of ocular toxoplasmosis in 8-year-old child**

**Authors :**

**Dr. Vinaya Kumar Konana**

**Dr. Bhagya M**

**Dr. Kalpana Babu**

## An interesting case of ocular toxoplasmosis in 8-year-old child

**Authors :** Vinaya Kumar Konana, Bhagya M, Kalpana Babu

Department of uveitis and ocular inflammation, Vittala International Institute of

Ophthalmology and Prabha Eye Clinic and Research Centre, Bengaluru, Karnataka, India

### **Introduction:**

*Toxoplasma gondii* is a coccidian parasite with worldwide distribution. Cats and other members of the feline family harbor these parasites acting as definitive hosts whereas humans act as intermediate hosts.<sup>[1]</sup> Most common source of infection is ingestion of contaminated water and raw or undercooked meat. The infection can be acquired prenatal or postnatal affecting both immunocompetent and immunocompromised hosts. We present a case of toxoplasma retinochoroiditis in a 9-year-old child.

### **Case report:**

A 9-year-old female child presented with floaters in the right eye. On examination visual acuity in both eyes was 6/6. Anterior segment examination of both eyes was unremarkable. Right eye fundus examination revealed a coin shaped yellowish retinal lesion with fuzzy borders temporal to the fovea with multiple pinpoint satellite lesions (Fig 1a). Optical coherence tomography through the lesion in the right eye showed full thickness involvement of retina with disruption of all retinal layers (Fig 1b). Left eye fundus examination was unremarkable. Serum IgG antibody to toxoplasmosis was 80.1 IU/ml (normal range being 1.6-3 IU/ml), and antibody to *Toxoplasma* IgM was 0.05 (Normal being <0.55), other investigations were not significant. Computed tomography scan of brain was within normal limits. She was treated with combination of Sulfamethoxazole and trimethoprim dose of 40 mg/kg/day and 8 mg/kg/day respectively given in two divided doses per day, along with Azithromycin 10mg/kg/day once a day dosing for 3 days. One week after initiation of therapy, she was symptomatically better. Visual acuity was 6/6. Right eye fundus examination revealed coin shaped yellow retinal lesion which was well demarcated indicative of a healing retinitis. She was then started on 5 mg oral prednisolone three times a day. Oral steroids were tapered slowly over 6 weeks. At 3 month follow up, she was doing well with visual acuity of 6/6 in both eyes, with right eye showing a healed toxoplasmosis scar (Figure 2) and no active vitritis.

### **Discussion:**

Ocular toxoplasmosis is one of the manifestations of systemic infection by *Toxoplasma gondii*. The infection can be acquired prenatal or post natal.<sup>[2]</sup> Congenital toxoplasmosis is associated with triad of hydrocephalus, intracranial calcification and chorioretinitis.<sup>[3]</sup> Ocular manifestations of congenital toxoplasmosis are usually in the form of chorioretinitis scar involving the posterior pole.<sup>[4]</sup> Usually acquired toxoplasmosis is asymptomatic in immunocompetent individuals and can manifest as

generalized lymphadenopathy or a flu-like illness.<sup>[5]</sup> It can be fatal in immunodeficient individuals.<sup>[6]</sup> Ocular manifestations of acquired toxoplasmosis in immunocompetent individual are seen in only 1% of individuals.<sup>[7]</sup>

Ocular toxoplasmosis in children presents in extremes of childhood with very few presenting between 4-9 years of age.<sup>[7]</sup> Our case presented at the age of 8, which is rare when compared to the usual trend. Approximately 50% of children with ocular toxoplasmosis acquire infection after birth.<sup>[7]</sup> Usually children with congenital ocular toxoplasmosis have bilateral involvement with posterior pole scarring and are detected on abnormal vision on routine screening.<sup>[4]</sup> Lesions of acquired toxoplasmosis are solitary, discrete, with an active focus of retinochoroiditis with no preexisting scars. Children, who acquire infection postnatal, usually present with acute symptoms like floaters, pain or blurred vision.<sup>[8]</sup> Table 1 shows characteristics of pediatric ocular toxoplasmosis reported in comparison with our case.<sup>[8,9,10]</sup>

Occurrence of ocular toxoplasmosis in extremes of childhood has been noted in various studies in the past.<sup>[8,11,12,13]</sup> It is believed that most of the children are affected in early childhood but ocular manifestations are noted later. It has been hypothesized that this delay is due to immunological mechanisms, possibly mediated by the hormonal changes of puberty, defer the occurrence of ocular lesions until adolescence or adulthood even when infection occurs in early childhood.<sup>[7]</sup>

Those having ocular involvement may present months after systemic infection.<sup>[14]</sup> Antibodies to IgM develop within 1-2 weeks of infection, whereas Ig G antibodies appear after 2 weeks of infection and peak at 1-2 months. Pathognomonic for recent infection is a seroconversion or an increase of toxoplasma IgG antibodies from a low to a high titre during a 3-week period.<sup>[15]</sup>

Pediatric patients with positive IgM without perinatal serologic information should be considered to be of uncertain origin as few authors have reported that patients with confirmed congenital toxoplasmosis may have persistent specific IgM-positive test up to 10 years of age.<sup>[16]</sup>

While treating children with ocular toxoplasmosis the dose should be calculated according to the body weight. Combination of sulfadiazine and trimethoprim at doses of 40 mg/ kg/day and 8 mg/kg/day respectively should be prescribed. Azithromycin 10mg/kg body weight can also be given in severe cases. This can be accompanied by anti-inflammatory corticoid therapy.

### **Conclusion:**

All pediatric ocular toxoplasmosis should not be presumed to be congenital. Though pediatric ocular toxoplasmosis is usually seen in extremes of childhood, it can be seen between 4-9 years as in our case. Effective treatment with per kg body weight dosing of systemic antibiotics and corticosteroid therapy is of importance in pediatric cases.

## References:

1. Donald H Medical parasitology. Jawetz EMelnick JLAAddberg EA Review of Medical Microbiology. 16th ed. Los Altos, CA Lange Medical Publication1984;517- 519
2. McAuley J. B. (2014). Congenital Toxoplasmosis. *Journal of the Pediatric Infectious Diseases Society*, 3 Suppl 1(Suppl 1), S30–S35.
3. Jones JL, Holland GN. Annual burden of ocular toxoplasmosis in the US. *Am J Trop Med Hyg.* 2010 Mar; 82:464-5.
4. Remington JS, McLeod R, Thulliez P, Desmonts G. Toxoplasmosis. In: Remington JS, Klein JO, Wilson CB, Baker CJ (eds). *Infectious Diseases of the Fetus and Newborn Infant*. 6th ed. Elsevier-Saunders: Philadelphia, 2006, pp 948–1091.
5. Melamed J, Eckert GU, Spadoni VS, Lago EG, Uberti F. Ocular manifestations of congenital toxoplasmosis. *Eye.* 2010 ;24:528
6. Saadatnia, G., & Golkar, M. A review on human toxoplasmosis. *Scandinavian Journal of Infectious Diseases.* 2012;44: 805–814.
7. Schmidt-Hieber M, Zweigner J, Uharek L, Blau IW, Thiel E. Central nervous system infections in immunocompromised patients: update on diagnostics and therapy. *Leuk Lymphoma.* 2009; 50:24-36.
8. M R Stanford, H K Tan, R E Gilbert. Toxoplasmic retinochoroiditis presenting in childhood: clinical findings in a UK survey. *Br J Ophthalmol* 2006; 90:1464–1467.
9. Garza-Leon M, Garcia LA.Ocular toxoplasmosis: clinical characteristics in pediatric patients. *Ocul Immunol Inflamm.* 2012;20:130-138.
10. Vania, G., Alessandra, V., Pilar, N., Francesca, P., Paola, E. and Gianvincenzo, Z. Ocular toxoplasmosis in an immunocompetent 8-year-old child: a new active lesion or a late manifestation of a congenital toxoplasmosis?. *Asian Pacific Journal of Tropical Disease.*2014; 4(4):.323-328.
11. Akstein RBWilson LADeutsch SM Acquired toxoplasmosis. *Ophthalmology.*1982;89 1299- 1302
12. Gilbert RE, Dunn DT, Lightman S, et al. Incidence of symptomatic toxoplasma eye disease: aetiology and public health implications. *Epidemiol Infect.* 1999;123:283–289.
13. Perkins ES. Patterns of uveitis in children. *Br J Ophthalmol* 1966;50:169–185.Manohar B. Balasundaram, MS; Raghuram Andavar, DNB; Manikandan Palaniswamy, MSc; et al Outbreak of acquired toxoplasmosis involving 248 patients. *Arch Ophthalmol.* 2010;128:28-32.Montoya JG. Laboratory diagnosis of *Toxoplasma gondii* infection and toxoplasmosis. *J Infect Dis.* 2002 Feb 15;185 Suppl 1:S73-82.
14. de-la-Torre A, Lopez-Castillo CA, Gomez-Marin JE. Incidence and clinical characteristics in a Colombian cohort of ocular toxoplasmosis. *Eye (Lond).* 2009;23:1090–1093.

**Table 1- Comparison of our case with published literature on pediatric ocular toxoplasmosis.**

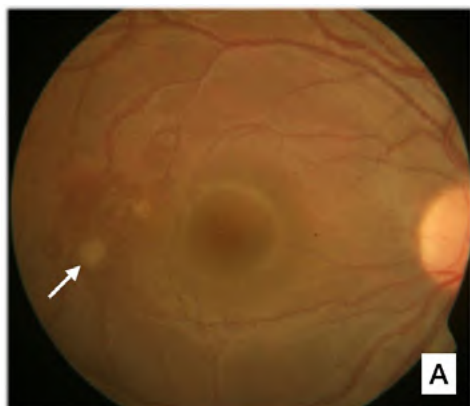	Authors	Location	Number of patients	Design of the study	Period of study	Age	laterality	Most common presenting symptom		Most common type of uveitis		Most common site of involvement
								Active disease	Inactive disease	Active disease	Inactive disease	
1	M. Garza-Leon et al	Mexico	40	Retrospective	1990 - 2005	9.5 ± 4.4 years	Bilateral (40%) Unilateral(60%)	Decreased vision	Strabismus	Pan uveitis	Posterior uveitis	Posterior pole
2	M R Stanford et al	United Kingdom	31	Prospective	2002-2004	<4 years – 12patients 4-10 years- 3patients >10 years – 14 patients	Bilateral (12.9%) Unilateral(87.1%)	Acute ocular symptoms	Most commonly presented after abnormal vision screening	NA		Posterior pole
3	Vania Getal	Taiwan	1	Case report	2014	8 years	Unilateral	Visual impairment		Healed macular lesion		Posterior pole
4	Our case	India	1	Case report	2019	9 years	Unilateral	Floaters		Active retinochoroiditis lesion at macula		Posterior pole

**Figure legends:**

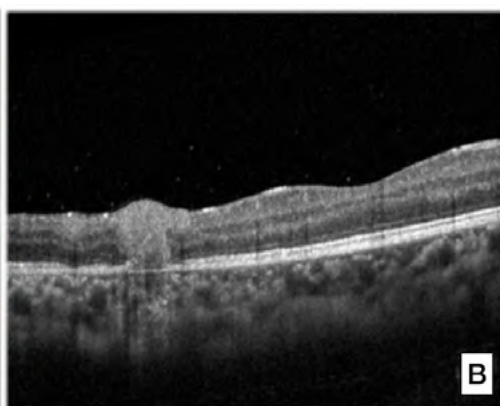
**Figure 1 A:** Fundus photograph of right eye showing yellowish retinal lesion with fuzzy borders temporal to the fovea with multiple satellite lesions. (white arrow)

**B:** Optical coherence tomography over the lesion showing full thickness involvement of retina with disruption of all retinal layers.

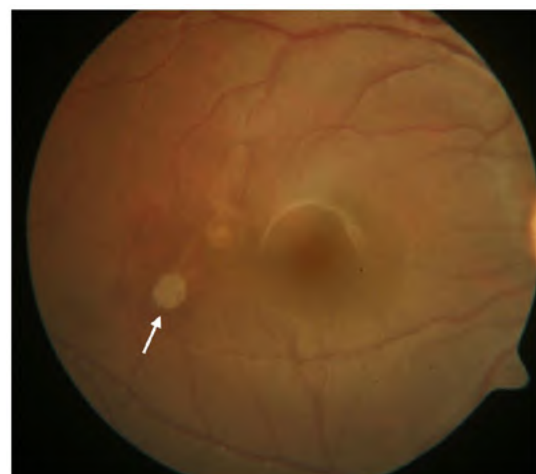**Figure 2:** Fundus photograph of right eye at 3 months follow up showing scarred lesion with well-defined border (white arrow)



**Figure 1 A**



**Figure 1 B**



**Figure 2**



# **What is new in Ocular Toxoplasmosis?**

**A 5-year summary of the published  
literature (original manuscripts and  
few important review articles)**

Authors:

Dr. Aniruddha Agarwal

Dr. Nitin Kumar Menia

Dr. Reema Bansal

## What is new in Ocular Toxoplasmosis?

### A 5-year summary of the published literature (original manuscripts and few important review articles)

Aniruddha Agarwal, Nitin Kumar Menia, Reema Bansal

Advanced Eye Center, Post Graduate Institute of Medical Education and Research (PGIMER), Chandigarh

#### 1. Diagnostics in Toxoplasmosis

Authors	Year	Title and Journal	Summary of Findings
Moghaddas E, Hosseini SM, Sharifi K, et al.	2019	IgG Avidity Test for Ocular Toxoplasmosis Diagnosis at a Tertiary Center, Northeast of Iran. <i>Iran J Immunol.</i> 2019 Sep;16(3):258-264.	IgG avidity testing results coincided with clinical diagnosis and it could therefore be considered to be a reliable method to differentiate between recently acquired and chronic ocular toxoplasmosis.
Greigert V, Di Foggia E, Filisetti D, et al.	2019	When biology supports clinical diagnosis: review of techniques to diagnose ocular toxoplasmosis. <i>Br J Ophthalmol.</i> 2019 Jul;103(7):1008-1012.	The authors have presented different techniques available for the biological diagnosis, along with their characteristics, and propose a diagnostic algorithm designed to select the best of these techniques if clinical examination is not sufficient to ascertain the diagnosis.
Rahimi Esboei B, Kazemi B, Zarei M, et al.	2019	Evaluation of RE and B1 Genes as Targets for Detection of <i>Toxoplasma gondii</i> by Nested PCR in Blood Samples of Patients with Ocular Toxoplasmosis. <i>Acta Parasitol.</i> 2019 Jun;64(2) : 384-389.	The nested PCR of peripheral blood is a useful and non-invasive method for detection of <i>T. gondii</i> in patients with ocular toxoplasmosis, especially in case of recently acquired infections, and RE targeted assay is more sensitive than B1 targeted assay for this purpose.
Gomez CA, Sahoo MK, Kahn GY, et al.	2019	Dual-target, real-time PCR for the diagnosis of intraocular <i>Toxoplasma gondii</i> infections. <i>Br J Ophthalmol.</i> 2019 Apr;103(4):569-572.	The single-reaction, internally controlled, dual-target (B1, Rep529) real-time PCR for the detection of <i>T. gondii</i> DNA in intraocular specimens demonstrated excellent agreement with nested, conventional, B1 PCR. The dual-target design may ensure <i>T. gondii</i> detection when variation is present in one of two target regions.



Mathis T, Beccat S, Sève P, et al.	2018	Comparison of immunoblotting (IgA and IgG) and the Goldmann-Witmer coefficient for diagnosis of ocular toxoplasmosis in immunocompetent patients. <i>Br J Ophthalmol.</i> 2018 Oct;102(10):1454-1458.	Immunoblotting seems to be more useful than the Goldmann-Witmer coefficient if only one of these methods can be performed, especially during the first three weeks after symptom onset.
Kumar A, Singh MP, Bansal R, et al.	2017	Development and evaluation of multiplex real-time PCR for diagnosis of HSV-1, VZV, CMV, and <i>Toxoplasma gondii</i> in patients with infectious uveitis. <i>Diagn Microbiol Infect Dis.</i> 2017 Nov;89(3):191-196.	The development of highly sensitive and specific assay for early differentiation of pathogens is important for the early initiation of treatment thereby preventing irreversible damage to the ocular structures.
Abd Elreheim AM, Farid AA, Mahana NA, et al.	2016	Sandwich-elisa development for the diagnosis of <i>Toxoplasma gondii</i> . <i>J Egypt Soc Parasitol.</i> 2016 Aug;46(2):429-440.	Sandwich-ELISA is a solid phase diagnostic method for detection of antigen or antibody that is used widely for diagnosis of protozoan and metazoan diseases of human and animals. In the present study, <i>T. gondii</i> SAG2 antigen was early detected in patient sera using Sandwich-ELISA. The PPV was 90.2% and NPV was 83.3%.
Robert-Gangneux F, Belaz S.	2016	Molecular diagnosis of toxoplasmosis in immunocompromised patients. <i>Curr Opin Infect Dis.</i> 2016 Aug;29(4):330-9.	Quantitative PCR methods with specific probes should be used to improve sensitivity and warrant specificity. Performance of quantitative PCR targeting the repeated 529 bp sequence for the diagnosis of toxoplasmosis in immunocompromised patients needs further evaluation.

Santos FF, Nascimento H, Muccioli C, et al.	2015	Detection of <i>Toxoplasma gondii</i> DNA in peripheral blood and aqueous humor of patients with Toxoplasmic active focal necrotizing retinochoroiditis using real-time PCR. <i>Arq Bras Oftalmol.</i> 2015 Nov-Dec;78(6):356-8	Real-time quantitative PCR (qPCR) was able to detect <i>T. gondii</i> DNA in patients with toxoplasmic active focal necrotizing retinochoroiditis in the blood as well as the aqueous humor and can help with the diagnosis of the disease.
Steeple LR, Guiver M, Jones NP.	2016	Real-time PCR using the 529 bp repeat element for the diagnosis of atypical ocular toxoplasmosis. <i>Br J Ophthalmol.</i> 2016 Feb;100(2):200-3.	The novel real-time PCR assay described is more sensitive than those targeting the <i>Toxoplasma</i> B1 gene owing to the higher number of repeats and highly conserved sequence level. This technique can be applied in clinical practice and provides a valuable tool for the rapid diagnosis of ocular toxoplasmosis.

## 2. Cytokines and Interleukins in Ocular Toxoplasmosis

Authors	Year	Title and Journal	Summary of Findings
Thieme C, Schlickeiser S, Metzner S, et al.	2019	Immune Mediator Profile in Aqueous Humor Differs in Patients with Primary Acquired Ocular Toxoplasmosis and Recurrent Acute Ocular Toxoplasmosis. <i>Mediators Inflamm.</i> 2019 Feb 17;2019:9356728.	This study for the first time shows subtle differences between the intraocular cytokine profiles in patients with either acute primary acquired ocular toxoplasmosis or recurrent ocular toxoplasmosis
de Faria Junior GM, Ayo CM, de Oliveira AP, et al.	2018	CCR5 chemokine receptor gene polymorphisms in ocular toxoplasmosis. <i>Acta Trop.</i> 2018 Feb;178:276-280.	Individuals with the CCR5/CCR5 genotype and simultaneously the CCR5-59029 AA or AG genotypes have a greater risk of developing ocular toxoplasmosis (4% greater), which may be associated with a strong and persistent inflammatory response in ocular tissue.
Maia MM, Meira-Strejevitch CS, Pereira-Chiocola VL, et al	2017	Evaluation of gene expression levels for cytokines in ocular toxoplasmosis. <i>Parasite Immunol.</i> 2017 Oct;39(10).	mRNA expression of 7 cytokines in ocular toxoplasmosis were statistically different from negative controls.

### 3. Imaging in Ocular Toxoplasmosis

Authors	Year	Title and Journal	Summary of Findings
Park JH, Lee SY, Lee EK.	2019	Morphological characteristics of ocular toxoplasmosis and its regression pattern on swept-source optical coherence tomography angiography: a case report. <i>BMC Ophthalmol.</i> 2019 Sep 5;19(1):199.	Swept-source optical coherence tomography (SS-OCT) imaging demonstrated diffuse choroidal dilation with many collateral vascular branches surrounding the active lesion. After the treatment, the toxoplasmic lesion resolved to an atrophic chorioretinal scar. Dilated choroidal vessel size was normalized and collateral vascular branches were markedly constricted on structural en face SS-OCT images.
Tsui E, Leong BCS, Mehta N, et al.	2019	Evaluation of segmental retinal arteritis with optical coherence tomography angiography. <i>Retin Cases Brief Rep.</i> 2019 Jul 15	Spectral domain OCT through areas of arteritis noted on clinical examination demonstrated areas of hyperreflectivity circumscribing the affected vessel with a normo-reflective lumen. Optical coherence tomography angiography and dense B-scan OCT angiography demonstrated narrowing of the intraluminal flow signal that correlated with areas of segmental hyperreflectivity on spectral domain OCT.
Yannuzzi NA, Gal-Or O, Motulsky E, et al	2019	Multimodal Imaging of Punctate Outer Retinal Toxoplasmosis. <i>Ophthalmic Surg Lasers Imaging Retina.</i> 2019 May 1;50(5):281-287.	Multimodal imaging is useful in diagnosing and monitoring treatment response in PORT, an uncommon presentation of ocular toxoplasmosis that must be differentiated from white dot syndromes or other causes of unilateral retinitis.
Türkcü FM, Şahin A, Yüksel H, et al.	2017	OCTA Imaging of Choroidal Neovascular Membrane Secondary to Toxoplasma Retinochoroiditis. <i>Ophthalmic Surg Lasers Imaging Retina.</i> 2017 Jun 1;48(6):509-511.	OCTA, a relatively new technique, is useful in the diagnosis of the CNVMs secondary to retinochoroiditis.

#### 4. Therapies for Ocular Toxoplasmosis

Authors	Year	Title and Journal	Summary of Findings
Tabuenca Del Barrio L, Heras Mulero H, Mozo Cuadrado M et al	2019	Intravitreal clindamycin as a therapeutic alternative in severe ocular toxoplasmosis. Arch Soc Esp Oftalmol. 2019 Oct 10.	Weekly intravitreal Clindamycin treatment is shown to be a suitable therapeutic alternative in cases of severe ocular toxoplasmosis and/ or in patients with a contraindication to classical treatment. Intravitreal Clindamycin treatment is a safe alternative with favorable clinical results.
Leesombun A, Iijima M, Umeda K, et al.	2019	Metacytofilin is a potent therapeutic drug candidate for toxoplasmosis. J Infect Dis. 2019 Oct 1.	With its potent anti-T. gondii activity, metacytofilin (MCF) from a fungal Metarhizium species is a strong candidate for future drug development against toxoplasmosis.
Casoy J, Nascimento H, Silva LMP, et al.	2019	Effectiveness of Treatments for Ocular Toxoplasmosis. Ocul Immunol Inflamm. 2019 Feb 26:1-7.	Both treatments, i.e. trimethoprim + sulfamethoxazole and pyrimethamine + sulfadiazine were effective for active episodes, with few side effects
Souza CE, Nascimento H, Lima A, et al.	2018	Intravitreal Injection of Sulfamethoxazole and Trimethoprim Associated with Dexamethasone as an Alternative Therapy for Ocular Toxoplasmosis. Ocul Immunol Inflamm. 2018;26(7):1041-1044.	The combination of intravitreal trimethoprim/sulfamethoxazole and dexamethasone might be an alternative treatment strategy in patients with toxoplasmic retinochoroiditis.
Fernandes-Cunha GM, Fialho SL, da Silva GR, et al.	2017	Ocular safety of Intravitreal Clindamycin Hydrochloride Released by PLGA Implants. Pharm Res. 2017 May;34(5):1083-1092.	PLGA implants containing clindamycin hydrochloride (CLH) appear safe and this study highlights this device as a therapeutic alternative for the treatment of ocular toxoplasmosis.
Fernandes Felix JP, Cavalcanti Lira RP, Cosimo AB, et al.	2016	Trimethoprim-Sulfamethoxazole Versus Placebo in Reducing the Risk of Toxoplasmic Retinochoroiditis Recurrences: A Three-Year Follow-up. Am J Ophthalmol. 2016 Oct;170:176-182.	Trimethoprim-Sulfamethoxazole may be used safely for prophylaxis of recurrent toxoplasmic retinochoroiditis, with long-term benefits.
Lima GS, Saraiva PG, Saraiva FP.	2015	Current Therapy of Acquired Ocular Toxoplasmosis: A Review. J Ocul Pharmacol Ther. 2015 Nov;31(9):511-7.	The study reviews the literature on the treatment and provide ophthalmologists with up-to-date information to help reduce visual morbidity. In conclusion, no ideal treatment scheme was identified; currently prescribed therapeutic schemes yield statistically similar functional outcomes.



# **It's not what it seems!: Multiple peripapillary retinitis lesions in Ocular Toxoplasmosis**

Authors:

Dr. Anirudh Soni

Dr. Mudit Tyagi

## It's not what it seems!: Multiple peripapillary retinitis lesions in Ocular Toxoplasmosis

Authors: Dr. Anirudh Soni, Dr Mudit Tyagi

L V Prasad Eye Institute, Hyderabad

### SUMMARY

A 32-year-old female presented with a chief complaint of blurred vision in the left eye since 3 weeks. Fundus examination revealed left eye multiple non confluent peripapillary retinitis patches, with macular edema. A clinical diagnosis of left eye viral retinitis was made. The patient underwent multiple intravitreal gancyclovir injections with no improvement. Finally an atypical presentation of toxoplasma retinitis was suspected and the patient underwent and responded well to intravitreal clindamycin with dexamethasone. A retinitis patch close to disc is an atypical presentations of ocular toxoplasmosis. However it responded well to anti parasitic therapy with steroid.

### BACKGROUND

Ocular toxoplasmosis is one of the most common cause of infectious retinochoroiditis in adults and children. It is caused by the obligate intracellular parasite *Toxoplasma gondii*. The typical presentation of ocular toxoplasmosis is characterized by focal retinochoroiditis adjacent to pigmented chorioretinal scar and vitreous inflammation<sup>1</sup>. In addition to the typical presentation of this disease, atypical forms of ocular toxoplasmosis have been observed. These include punctuate outer retinal toxoplasmosis, retinal vasculitis, retinal vascular occlusion, rhegmatogenous and serous retinal detachment, optic neuropathy, and scleritis<sup>2</sup>. In this case report, we highlight an atypical presentation of ocular toxoplasmosis along with the OCT findings in a young female.

### CASE PRESENTATION

A 32 year healthy female presented with sudden painless blurring of vision in her left eye since 20 days, with no complaints in the right eye. On examination, RE vision was 20/20. The anterior & posterior segment examination was within normal limits. LE vision was 20/320, N60, not improving with correction. Anterior segment showed multiple fine keratic precipitates with cells grade 2+ in the anterior chamber. Posterior segment revealed minimal vitritis with multiple non confluent peripapillary retinitis patches of size 2-3 disc diameter nasally & superiorly to disc. Macular edema was also present. There were no peripheral lesions. Based on clinical examination & OCT features, a diagnosis of LE viral retinitis was made and the patient received 4 intravitreal gancyclovir + dexamethasone injections 1 week apart within a month's duration as some lesions showed regression. The patient was also started on oral steroids.

After 4 injections of gancyclovir, the vision improved to 20/80, N12. The superior peripapillary retinitis patch was still persisting. A clinical suspicion of atypical toxoplasmosis was made. The patient was taken up for vitreous biopsy with intravitreal clindamycin with dexamethasone. Vitreous toxoplasma IgG & Igm titres came out positive. The patient was then started on oral Bactrim DS.

After two months of oral anti toxoplasma therapy, the vision improved to 20/30 N6. All retinitis patches healed with the presence of ERM nasal to macula.

## DISCUSSION

---

This case is an atypical presentation of ocular toxoplasmosis based on the presentation of multiple retinitis patches close to disc, and minimal of vitritis. However, a high degree of clinical suspicion & the positive serology confirmed the diagnosis.

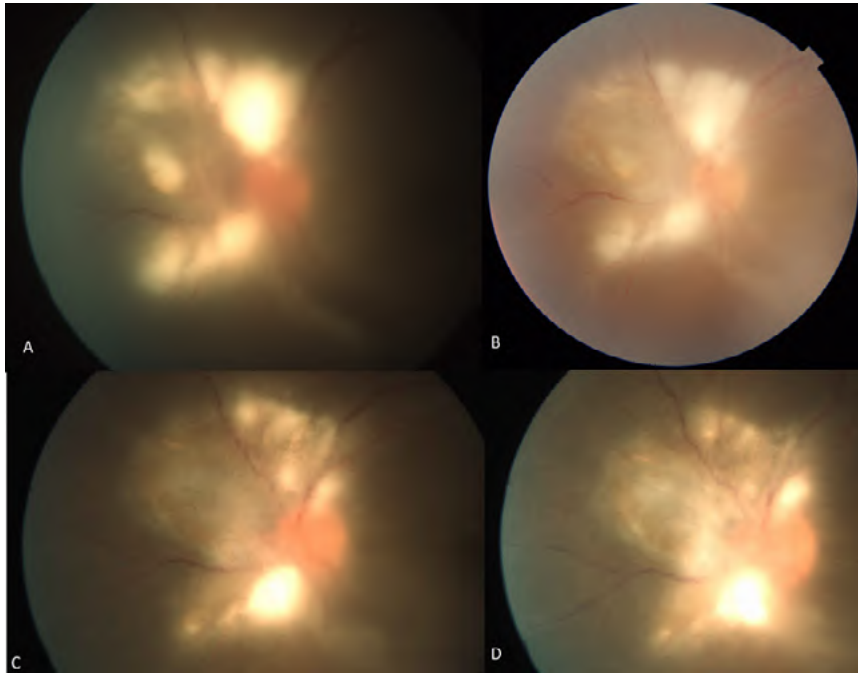
Vitreous inflammation is usually more intense near the active retinochoroiditis. However, minimal or no vitritis can be observed when the inflammation is distant from the inner retina specially if it does not exceed the inner limiting membrane towards the vitreous<sup>1</sup>. In our case, there was minimal vitritis inspite of the active inflammation involving all the retinal layers & minimal involvement of choroid as seen on OCT scans described subsequently.

A variety of less common, “atypical” presentations may be unfamiliar to clinicians, delaying both diagnosis and treatment. Patients who are immunocompromised or elderly may present with large, multiple and/or bilateral lesions. Other unusual manifestations include punctate outer retinal toxoplasmosis, retinal vasculitis, retinal vascular occlusions, rhegmatogenous and serous retinal detachments, a unilateral pigmentary retinopathy mimicking retinitis pigmentosa, neuroretinitis and other forms of optic neuropathy, and scleritis<sup>2</sup>.

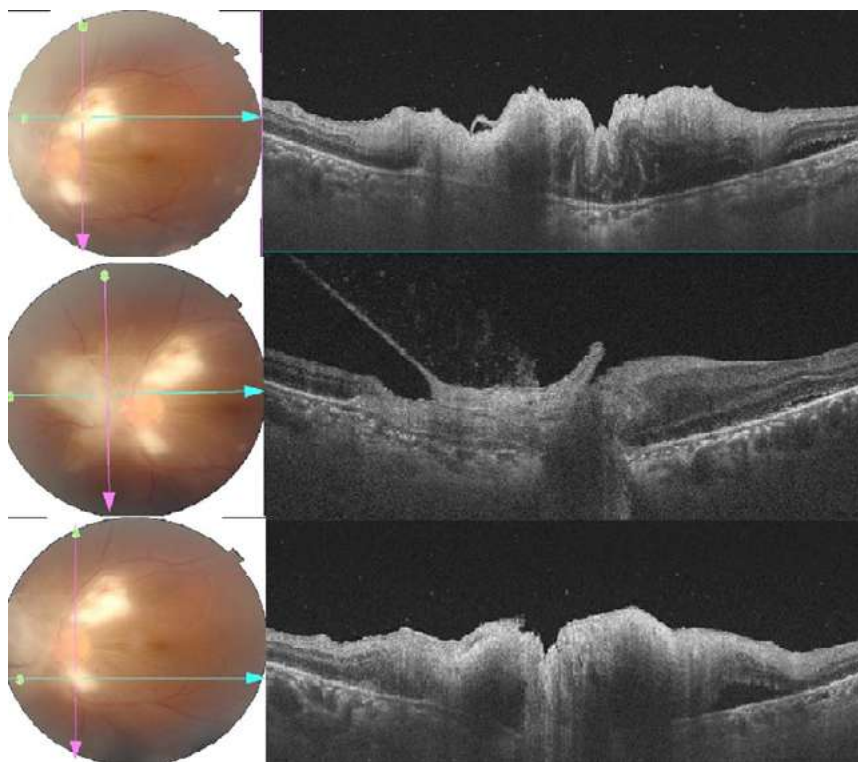
Previously described OCT features of toxoplasma retinitis include vitritis, hyaloid thickening, retinal thickening, interruption of photoreceptor IS/OS, RPE elevation & hyporefectivity of choroid<sup>3</sup>. Invernizzi et al have described newer OCT features of toxoplasma retinitis. They have noted hyper reflective round deposits along the posterior hyaloid, retrohyaloid hyper-reflective spots, epiretinal membrane, intraretinal edema, hyper-reflective vertical strips in ONL and a disruption of the choroidal architecture<sup>4</sup>.

A careful history, thorough examination, and a tailored work up cannot be over emphasized in suspect cases. We preferred coverage with antiparasitic agents as the patient did not respond to antiviral therapy and a positive serology. In summary, this case was an atypical manifestation of ocular toxoplasmosis presenting as multiple non confluent peripapillary retinitis patches which resolved in response to appropriate therapy.

## FIGURES

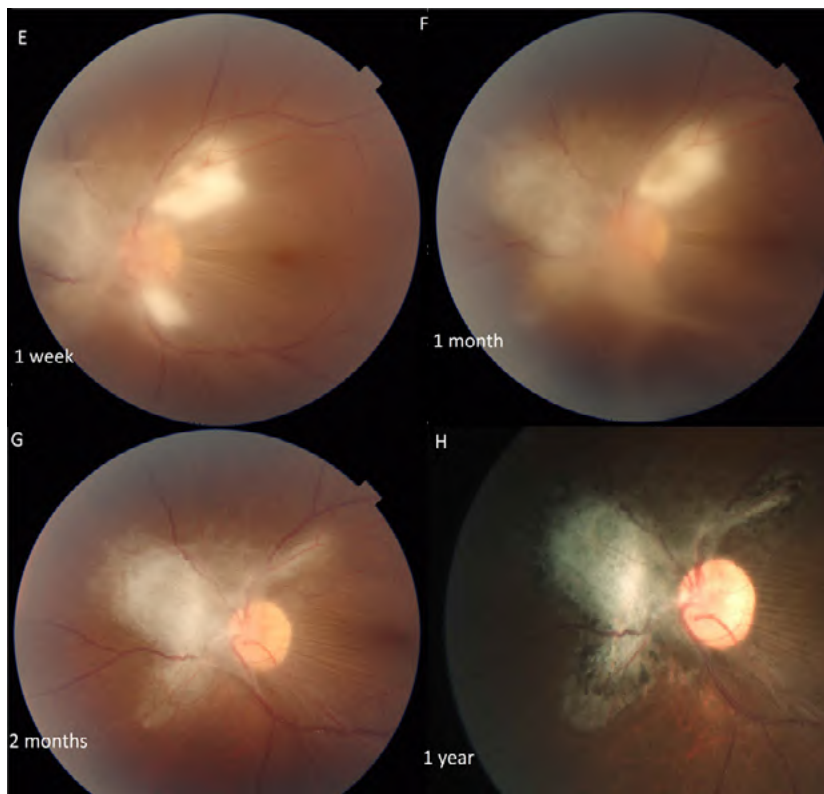


**Figure 1-** Serial colour fundus photographs (A-D), each following one injection of gancyclovir with dexamethasone, over a duration of one month. The retinitis lesions are reducing in size, but persisting.

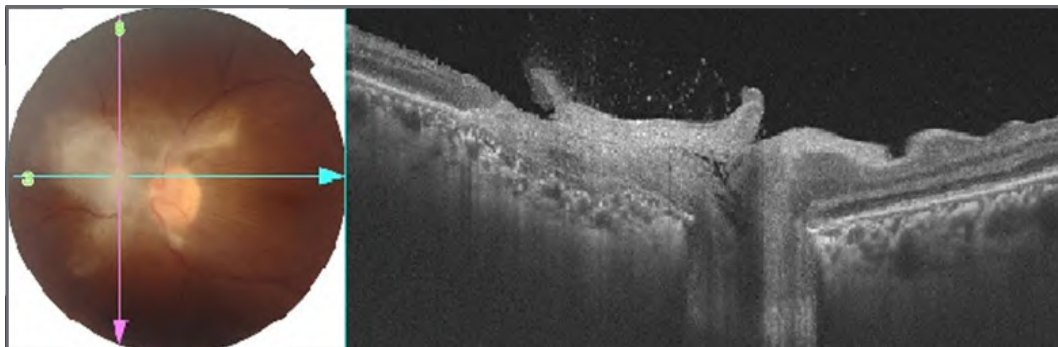


**Figure 2 -** OCT line scan passing through all peripapillary retinitis patches before administration of gancyclovir injection. There are hyper reflective dots in the posterior vitreous. The posterior hyaloid is thickened and adherent to the retina, with hyperreflectivity and thickening of all retinal layers. There is presence of hyperreflective dots in the subretinal space with some fluid. The RPE cannot be distinctly made out. The choroid appears hyporeflective.





**Figure 3-** Serial colour fundus photographs (E-F) following a single injection of clindamycin with dexamethasone. The retinitis patches resolved with formation of peripapillary scar and ERM nasal to fovea.



**Figure 4 -** OCT line scan passing through a peripapillary retinitis patch 2 months following injection of clindamycin & dexamethasone. The posterior vitreous hyperreflective dots are persisting. The posterior hyaloid is densely adhered to retinal surface. The retinal hyperreflectivity has reduced, signifying regression of active retinitis and scar formation. The RPE is faintly seen. The choroid hypo reflectivity is reduced.

## REFERENCES

1. Delair E, Latkany P, Noble AG, Rabiah P, McLeod R, Brézin A. Clinical manifestations of ocular toxoplasmosis. *Ocul Immunol Inflamm.* 2011;19:91–102
2. Smith JR, Cunningham ET., Jr Atypical presentations of ocular toxoplasmosis. *Curr Opin Ophthalmol.* 2002;13:387–92. [PubMed: 12441842]
3. Khairallah M, Kahloun R, Ben Yahia S, Jelliti B. Clinical, tomographic, and angiographic findings in patients with acute toxoplasmic retinochoroiditis and associated serous retinal detachment. *Ocul ImmunolInflamm.* 2011;19:307–10
4. Invernizzi A, Agarwal AK, Ravera V, Mapelli C, Riva A, Staurengi G, McCluskey PJ, Viola F. Comparing optical coherence tomography findings in different aetiologies of infectious necrotising retinitis. *Br J Ophthalmol.* 2018 Apr;102(4):433-437



**Title:**

**Role of IgG Avidity test and  
intravitreal Clindamycin in a  
pregnant female with ocular  
Toxoplasmosis**

**Authors:**

**Dr. Lagan Paul**

**Dr. Manisha Agarwal**

# **Title: Role of IgG Avidity test and intravitreal Clindamycin in a pregnant female with ocular Toxoplasmosis**

**Authors:** Dr. Lagan Paul, MS, DNB,FICO ;Dr. Manisha Agarwal MS, DNB

**Institutional Address:** Dr. Shroff's Charity Eye Hospital, 5027- Kedar Nath Road, Daryaganj  
New Delhi-110002. India

**Email Address:** Dr. Lagan Paul- laganpaul@gmail.com; Dr. Manisha Agarwal- manisha@sceh.net

**Running title:** Ocular toxoplasmosis in pregnancy

**Financial Interest:** We have no financial interest

**Abstract:** BACKGROUND: Congenital Toxoplasmosis is caused by maternal infection during gestation with maximum risk of transmission in the third trimester. Ocular toxoplasmosis in pregnancy has a similar risk of transmission to the fetus and therefore a decision to terminate or continue the pregnancy has to be made along with the safest route of administration of drugs in the mother. Oral administration of antitoxoplasma drugs is recommended along with intravitreal clindamycin to avoid vertical transmission. IgG Avidity test in the mother helps to predict the risk of transmission in the fetus.

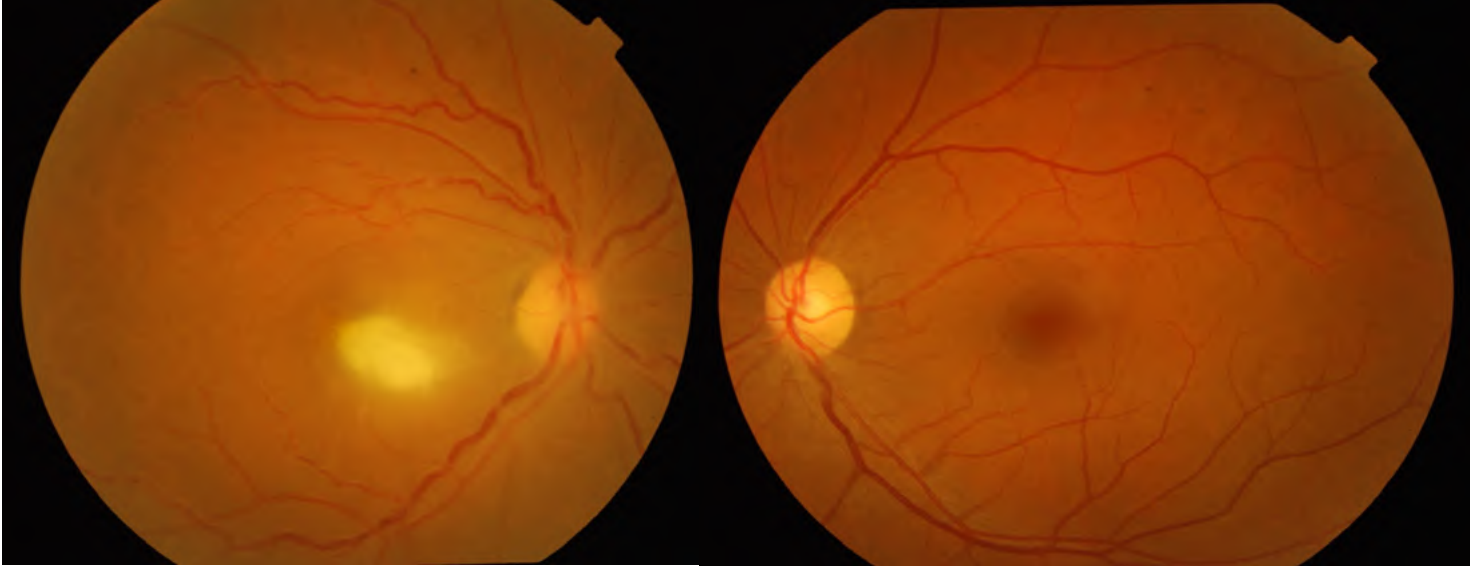
**CLINICAL FINDINGS:** A 32 year old pregnant woman presented with diminution of vision in the right eye. She had a Clininal focal retinitis lesion with overlying vitritis. She was diagnosed with acquired ocular toxoplasmosis. She was IgG positive and IgM negative for toxoplasma. Anti-toxoplasma IgG avidity test was performed. She was treated with intravitreal injections of clindamycin and dexamethasone and the pregnancy was continued. No signs of ocular toxoplasmosis were found in the neonate. Anti-toxoxoplama IgG titres in umbilical cord blood sample was positive but IgM titres tested at day 5 after birth was negative in the neonate.

**CONCLUSION:** Intravitreal injection of clindamycin with dexamethasone may be an acceptable alternative to treat active ocular toxoplasmosis in pregnancy without any systemic medication. It may provide a safer treatment alternative with no risk of teratogenic side effects, and more convenience requiring less hematological evaluations and follow up visits.

**INTRODUCTION:** Ocular toxoplasmosis(OT) in a pregnant female has a risk of transmission to the fetus causing congenital toxoplasmosis. IgG Avidity test titres helps to predict the risk of transmission to the fetus and helps to decide the termination of pregnancy. The management of OT in a pregnant female is difficult to manage-firstly due to avoidance of systemic medication and secondly due to the risk of transmission to the fetus requiring a termination of the pregnancy. Intravitreal clindamycin and oral spiramycin is recommended to avoid the transmission to the fetus. We report the first case of a pregnant female with OT which was managed with intravitreal clindamycin and dexamethasone (IVCD) without any systemic medication. The neonate showed no signs of congenital toxoplasmosis on testing the umbilical cord sample, serological testing and ocular examination.

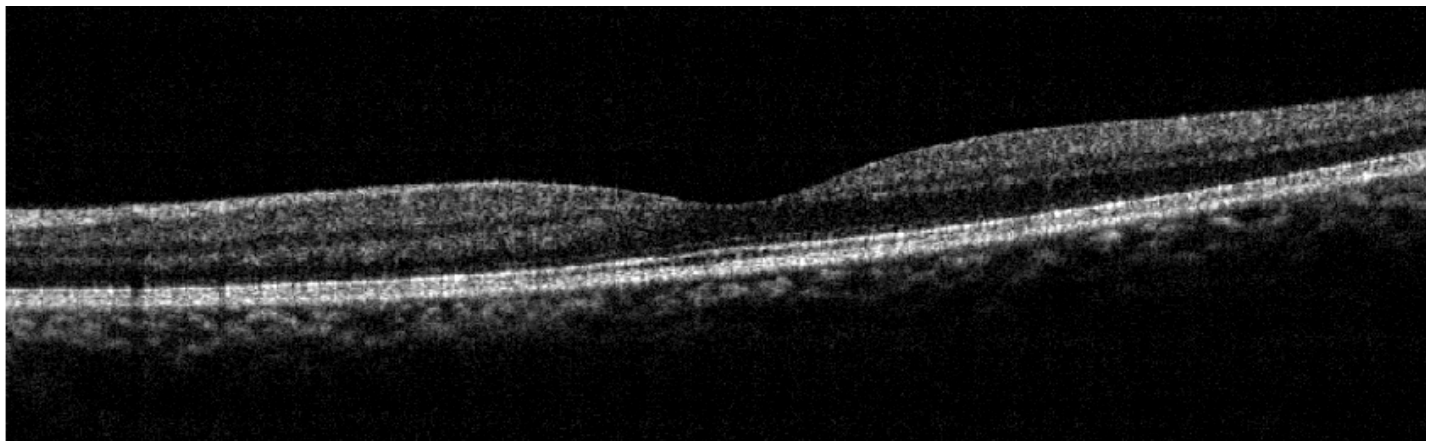
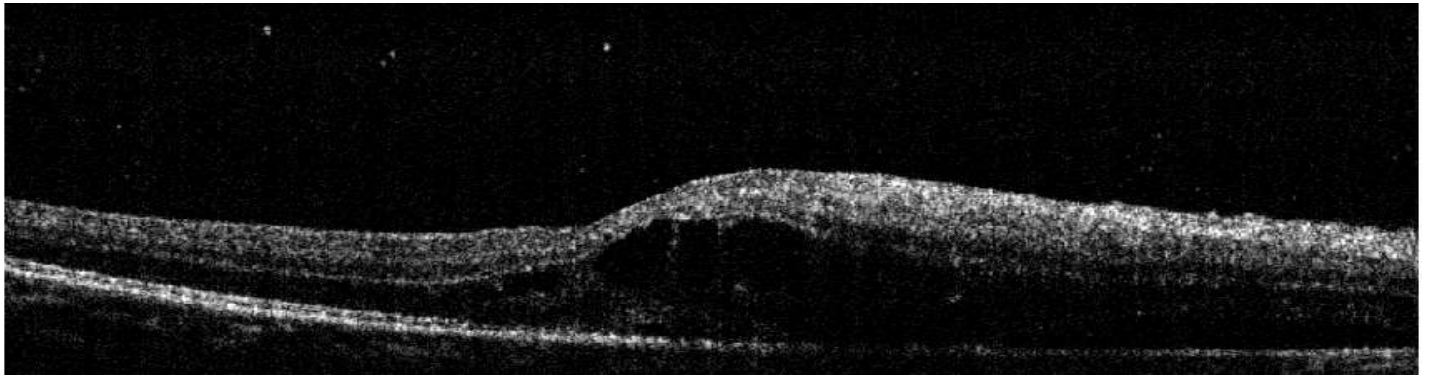
## CASE DESCRIPTION

A 32 year old female patient with 18 weeks of pregnancy presented with blurring of vision in the right eye for last 1 week. There was no past relevant ocular or systemic history. On examination, the best corrected visual acuity was 6/36, N18 in the right eye and 6/6, N6 in the left eye. Anterior segment examination was normal in both the eyes. Applanation tonometry was 12 mm Hg in both the eyes. Fundus examination showed a diffuse, horizontally oval elevated, yellowish white lesion measuring half disc size vertically and one disc diameter horizontally inferior to macula with overlying vitritis.(Fig-1)



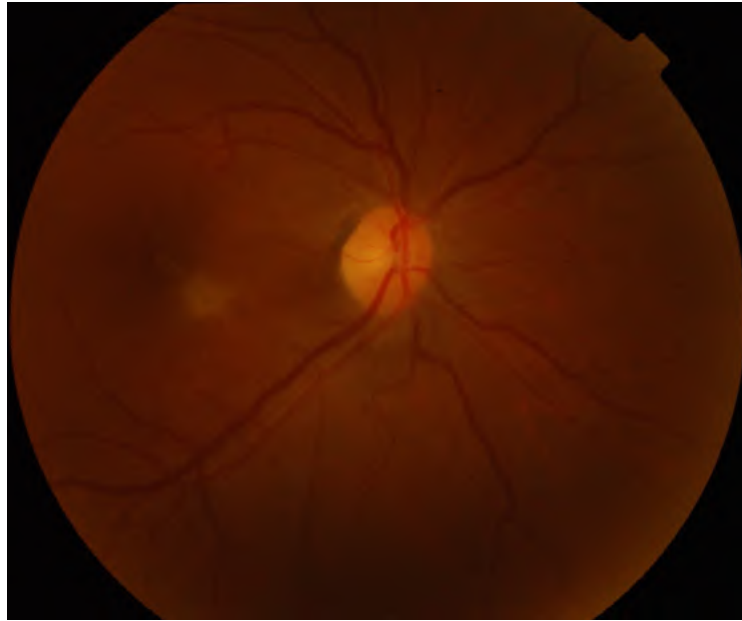**Fig1: At Presentation**

There was associated peripheral perivascular sheathing in all the quadrants and the left eye was within normal limits. Optical coherence tomography (OCT) showed marked macular thickening.(Fig-2)

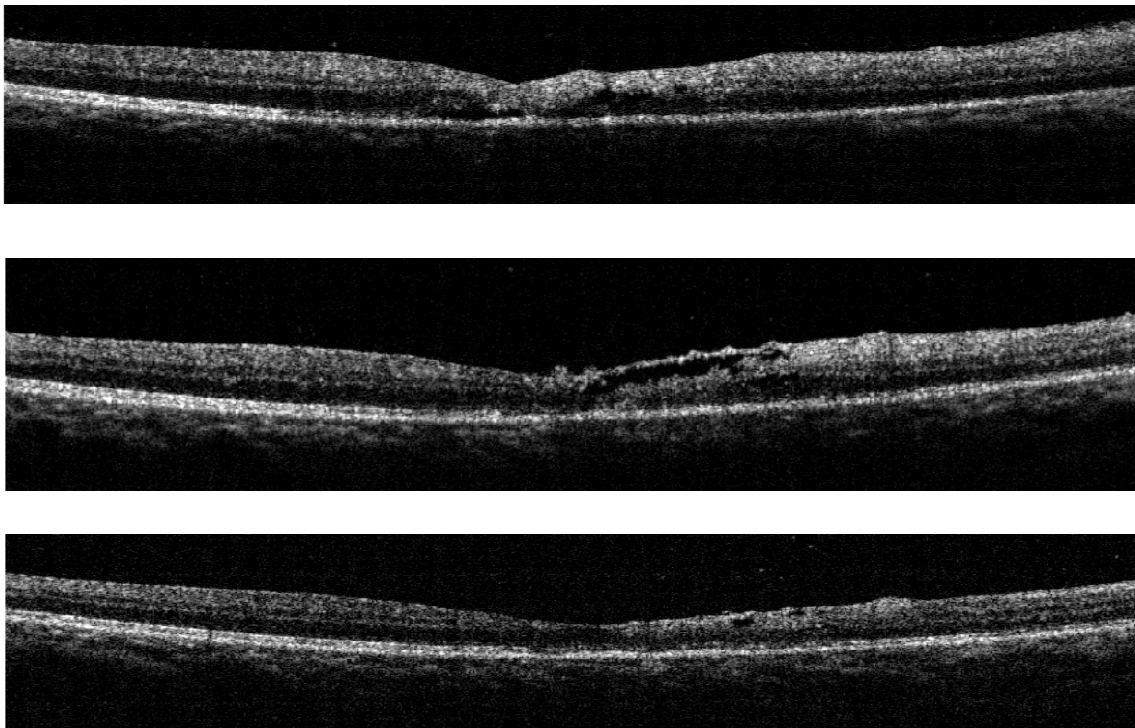


**Fig 2: OCT at presentation**

Fundus Fluorescein Angiography(FFA) was avoided as the patient was pregnant. Serological evaluation was done which showed IgM toxoplasma level as 0.29 IU/ml (range: negative <0.9, positive >1.0-1.1 IU/ml) and IgG titer value for toxoplasma was >300 IU/ml (range: negative < 4IU/ml, positive >8 IU/ml). Anti-toxoplasma IgG Avidity level was 0.466 (value =>0.300 is high avidity IgG). In consultation with the treating obstetrician she was given an intravitreal clindamycin 1.5mg/0.1ml and dexamethasone 400 µg/0.1ml injection in the right eye under topical anesthesia and strict aseptic precautions. Follow-up visit at 2 weeks showed the best corrected visual acuity in the right eye as 6/24,N9. Second intravitreal injection of same drugs was repeated after 1 month of the first injection. No systemic treatment was given and she was asked to continue with the pregnancy. Fundus examination of the right eye showed regression of the active lesion with the resolution in the vitritis.(Fig-3,4)



**Fig 3: Follow up at 2 months**



**Fig 4: OCT follow ups**

Her final best corrected visual acuity was 6/12,N6. She delivered a full term healthy baby girl. Umbilical cord blood sample was taken and sent for serological investigations. IgG anti-toxoplasma antibody titres was 147 IU/ml (Reference value: negative <7.1 IU/mL, positive >8.8 IU/mL) in the umbilical cord blood sample. Blood sample was taken from the neonate on day 5 after birth which showed IgM anti-toxoplasma titres to be < 3.0 AU/mL (non-reactive if <6.0 AU/mL, reactive >8AU/ml). Fundus examination of both the eyes of the neonate was normal with no evidence of any retinal lesion.

## DISCUSSION

Toxoplasmosis is a disease caused by intracellular unicellular protozoan *Toxoplasma gondii*.<sup>1st</sup> It may be an acquired or congenital toxoplasmosis. It is commonly believed that females with a history of OT are at an increased risk for recurrent ocular disease during pregnancy attributable to hormonal or immunologic changes that are known to occur during pregnancy. 2-4 Congenital toxoplasmosis is a result of maternal infection during pregnancy. A thorough evaluation and serological screening test for toxoplasmosis during pregnancy is mandatory. Vertical transmission rate of *Toxoplasma gondii* is reported to increase with advancing trimester of pregnancy, being 3% in the first trimester, 22% in the second, and 63% in the third trimester.<sup>5</sup> Early infections during pregnancy lead to intrauterine deaths and still births but infections late in gestation present with normal appearing neonates with chorioretinitis and neurological deficits. The classical clinical triad of congenital toxoplasmosis is chorioretinitis, hydrocephalus and intracranial calcification. Management of ocular toxoplasmosis in a pregnant female is always a challenge because one needs to decide regarding the risk of transmission of infection to the fetus thereby requiring a termination of the pregnancy and secondly we need to avoid systemic medications because of their teratogenic side effects.

Anti-Toxoplasma immunoglobulin G (IgG) avidity test is a diagnostic method intensively used to differentiate a recent and more distant *Toxoplasma gondii* infection in a single serum sample. Low IgG avidity test titres show a recently acquired infection and high titers show an infection acquired atleast more than equal to 4 months.

On review of literature, it is recommended that a combination of intravitreal clindamycin and oral spiramycin is the safest to treat toxoplasmosis in a pregnant female. Oral spiramycin is said to be essential to avoid the transmission of the infection in the fetus. However, in our case we treated the pregnant female with intravitreal clindamycin and dexamethasone injections (IVCD) without any systemic medications. Subsequently we tested the umbilical cord sample and blood sample of the neonate. There was presence of high IgG antibody titres in the umbilical cord sample which are transferred from the mother to the fetus and the blood sample of the neonate showed low IgM titres which show absence of congenital toxoplasmosis. On ocular examination of the newborn, there was no evidence of retinochoroidal lesions and systemic evaluation was within normal limits. We report this case to highlight the role of pregnant female with OT treated with IVCD only without any concomitant systemic medication such as oral corticosteroids and anti-toxoplasma drugs, and serological testing done in the neonatal blood and umbilical cord sample for excluding congenital toxoplasmosis.<sup>6</sup> The classic treatment of toxoplasmosis retinochoroiditis in pregnancy is systemic administration of spiramycin or clindamycin and systemic corticosteroid. Spiramycin is effective in reducing the risk of transmission to the fetus and therefore needs to be given throughout pregnancy. Pyrimethamine, sulfadiazine use in pregnant women is not known to be safe and not advisable. Other alternative treatments for ocular

toxoplasmosis are quadruple drug therapy (classic regimen plus clindamycin), trimethoprim and sulfamethoxazole, minocycline, azithromycin, atovaquone, and clarithromycin 7<sup>th</sup>.

**CONSENT:** A written well-informed consent was obtained from the patient for publication of this report and also accompanying images.

## REFERENCES

1. Hogan MJ (1961) Ocular toxoplasmosis in adult patients. *Surv Ophthalmol* 6:835-51.
2. Garweg JG, de Groot-Mijnes JDF, Montoya JG (2001) Diagnostic approach to ocular toxoplasmosis. *Ocul Immunol Inflamm* 19:255–261.
3. Jenum PA, Stray-Pedersen B, Melby KK, Kapperud G, Whitelaw A, Eskild A, Eng J (1998) Incidence of *Toxoplasma gondii* infection in 35,940 pregnant women in Norway and pregnancy outcome for infected women. *J Clin Microbiol* 36(10):2900-6.
4. Kump LI, Amdroudi SN, Foster CS (2005) Ocular toxoplasmosis in pregnancy. *Clin Exp Ophthalmol* 33:455-60.
5. Wallon M, Dunn D, Slimani D, Girault V, Gay-Andrieu F, Peyron F (1999) Diagnosis of congenital toxoplasmosis at birth: what is the value of testing for IgM and IgA? *Eur J Pediatr* 158:645–9.
6. Soheilian M, Ramezani A, Azimzadeh A, Sadoughi MM, Dehghan MH, Shahghadami R, Yaseri M, Peyman GA (2011) Randomized Trial of Intravitreal Clindamycin and Dexamethasone versus Pyrimethamine, Sulfadiazine, and Prednisolone in treatment of ocular toxoplasmosis. *Ophthalmology*. 118(1):134-41. doi:10.1016/j.opthta.2010.04.020.
7. Hedman K, Lappalainen M, Seppäiä I, Mäkelä O (1989) Recent primary toxoplasma infection indicated by a low avidity of specific IgG. *J Infect Dis* 159(4):736-40.





**Title:**  
**Atypical Toxoplasmosis-**  
**A review**

Authors:

Dr. Dipankar Das

Dr. Tanvi Gupta

Dr. Harsha Bhattacharjee

## Title: Atypical Toxoplasmosis- A review

Dr. Dipankar Das, Dr. Tanvi Gupta, Dr. Harsha Bhattacharjee  
Sri Sankaradeva Nethralaya, Guwahati, INDIA

Ocular Toxoplasmosis (OT) is the most frequent identifiable cause of posterior uveitis in many countries worldwide<sup>1</sup>. In India, there seems to be a diminishing trend of OT amongst the specific causes of posterior uveitis. However, amid the infectious causes, it is still one of the important causes of posterior uveitis along with bacterial and viral retinitis.<sup>2-8</sup> OT mainly affects individuals in the second to the fourth decade of life in the immune-competent cluster of the population.<sup>9</sup> The adverse impact of the disease in terms of loss of socio-economic productivity for the individual and his/her family is thus, noteworthy. Sound information of various atypical presentations of toxoplasmosis can help speed-up the diagnosis in these cases and thus help in administering suitable cure when needed and preventing avoidable complications. Laboratory confirmation or response to precise treatment can further assist in confirming the diagnosis. Though the disease is self-limiting, treatment in OT is instituted by ophthalmologists where they aim at limiting the growth of tachyzoites during the active phase of the ocular disease so that the size of the final scar is lesser.<sup>10</sup>

In a survey done at two uveitis meetings in Hyderabad, it was established that most of the Indian ophthalmologists (75.6%) found atypical OT in less than one-fourth of their patients with OT. Only 3 of the 37 ophthalmologists surveyed diagnosed atypical OT in more than 75% of OT cases seen by them. All of them belonged to the group attending to more than 20 new patients with uveitis every month and were practicing at tertiary care centres with access to laboratory facilities for Polymerase Chain Reaction (PCR) and intra-ocular antibody testing. The researchers assumed the reasons for possible under-diagnosis of the condition; first being a lack of awareness of the atypical presentations of OT, second that the disease is self-limiting and patients mostly improve before an appropriate diagnosis is made and thirdly, due to the lack of availability of standard laboratory facilities to establish diagnosis in difficult cases. Most common atypical presentations reported in the survey were full-thickness retino-choroiditis in absence of adjacent scars (81.1%) and neuro-retinitis (18.9%).<sup>11</sup>

**Typical Toxoplasmosis:** History of a typical OT would include one or more of decreased vision, pain and floaters. Typical active lesion consists of a yellow-white nidus of retino-choroiditis (Head light in fog- appearance)[ Figure 1] with fluffy borders adjacent to a pre-existing, usually pigmented retino-choroidal scar. There can be changing degrees of vitritis presenting as vitreous cells and vitreous haze. In immuno-competent patients, these lesions resolve of its own accord within 4-8 weeks leaving a remaining scar. The active disease is mostly one-sided.

Figure 1: Fundus picture of right eye showing active typical toxoplasma retinochoroidal lesion with intense vitritis (Head light in fog appearance).

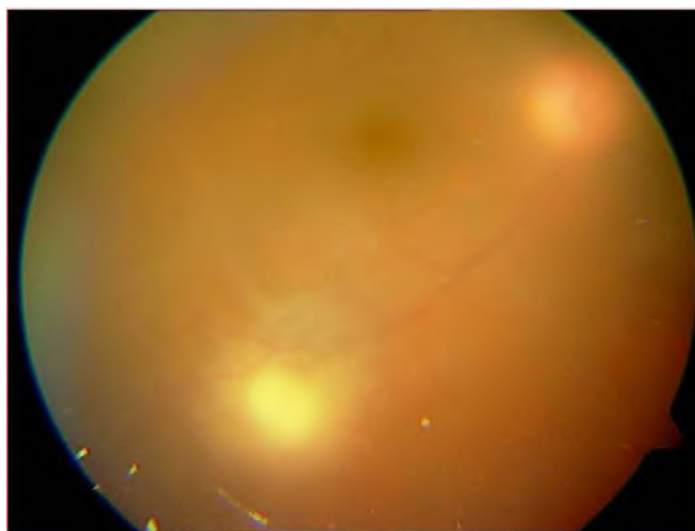


Figure 1

**Atypical Toxoplasmosis:** Host factors i.e. age, immune status, and pregnancy; parasite factors and environmental features influence the severity and hence, the presentation of OT.<sup>12</sup>

**Severe forms** – these are mostly seen in old aged or in patients with AIDS or other causes of systemic immune-suppression.

**Old age-** Large lesions, higher rate of complications and disease with poor visual prognosis might be seen in elderly individuals. Older age is associated with higher vitreous cells or vitreous haze scores.<sup>13</sup> Diffuse or multifocal necrotizing retinopathies confusing the diagnosis with acute retinal necrosis syndrome mostly seen in viral aetiologies -Varicella Zoster Virus (VZV) , Herpes Simplex Virus (HSV) and Cytomegalovirus (CMV) might also be present and this differential diagnosis should be kept in mind while dealing with such presentations in elderly.<sup>14</sup> Higher rates of severe disease in aged might be explained by the weaker cell-mediated immunity, lower levels of nutrition and presence of chronic underlying diseases. Elderly individuals are also more frequently found to present with OT in the acute phase of systemic Toxoplasma infection rather than in the chronic phase.<sup>9,14,15</sup>

**Acquired immune-deficiency syndrome (AIDS)-** In patients with co-existent HIV infections ( AIDS) and OT, the presentation can include a frequent bilateral or multifocal disease [Figure 2].<sup>16,17</sup> Lesions may be several disc diameters large.<sup>18</sup> A pre-existing retino-choroidal scar may not be present suggesting recently acquired infection or dissemination of virus from other sites. They can have severe retinal necrosis<sup>17, 18</sup> leading to retinal tears or retinal detachments in some of them. Cerebral toxoplasmosis may be present in many of these patients and systemic evaluation is necessary to diagnose the same and begin treatment to reduce the rate of morbidity and mortality associated with it.<sup>16,18</sup> Concurrent intra-ocular infections with other organisms like Cytomegalovirus (CMV) and Herpes Simplex *Virus* might be present and can also develop in subsequent follow-ups over a few months.<sup>16,19</sup>

Figure 2: Multifocal atypical toxoplasma retinochoroidal lesions in HIV positive patient. Other eye also had similar lesions.

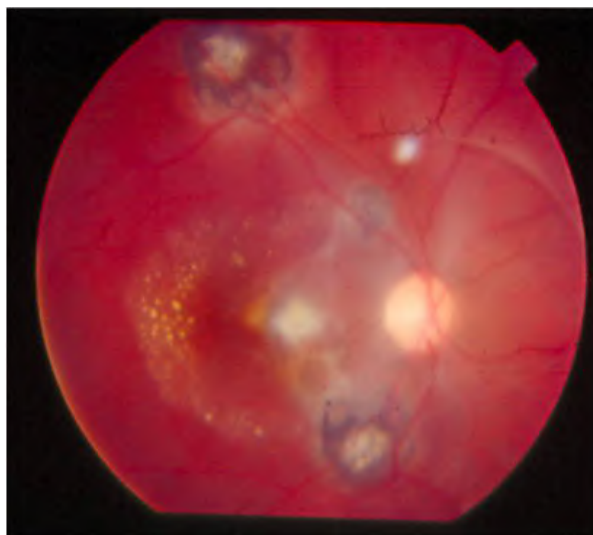


Figure 2

Moorthy et al have reported two cases where the necrotizing retinitis spread and lead to a panophthalmitis and subsequently, orbital cellulitis leading to a complete loss of vision. Hence, the need of keeping *Toxoplasma* as a differential diagnosis in mind in a patient with necrotizing retinitis in the setting of AIDS along with other aetiologies i.e. CMV, progressive outer retinal necrosis and Syphilis.<sup>18,20</sup>

Anti-toxoplasma antibody titres might not be raised significantly due to the compromised immune status of these individuals.<sup>18</sup> Optic nerve involvement, exudative retinal detachments and branch retinal artery occlusions have also been reported in OT with AIDS.<sup>18</sup> Steroids should not be administered in patients with AIDS with OT as it can increase the risk of development of severe infections.

**Other systemic immunosuppressive conditions-** Balansard and associates report a case series of 16 patients in whom anti-viral therapy was initiated suspecting acute retinal necrosis syndrome (ARN). Subsequently, on basis of laboratory confirmation or response to specific therapy the final diagnosis was arrived at; and Toxoplasmic retinochoroiditis was present in 10 of these 16 patients (62.5%). 9 of these 10 cases had a systemic immunosuppression; they were receiving systemic corticosteroids, immunosuppressive therapy or having hematological abnormalities, thymoma or HIV.<sup>21</sup> Though presence of vitritis may preclude detailed view, Toxoplasmic retinitis can be differentiated from CMV retinopathy by its thick dense yellowish-white color, smooth non-granular borders, and lack of hemorrhages.<sup>22</sup>

Yusuf et al report a very challenging case of an 81 year old man who was on systemic immune-suppressives for rheumatoid arthritis and had a history of radical nephrectomy for unilateral hypernephroma. This patient presented with panuveitis, a confluent chorio-retinal atrophic patch and a large area of multiple foci of active retinitis superonasal to disc 4 weeks after an uneventful cataract surgery in his left eye. The lesion continued to progress towards the disc even after anti-viral therapy. Finally, vitreous tapping for Toxoplasma was requested and found to be positive. Patient had already been started on oral Azithromycin after negative PCR assays for CMV, VZV and HSV; negative vitreous biopsy for malignant cells; normal chest X-ray, normal serum angiotensin converting enzyme levels and negative serology for syphilis and HIV PCR. Intravitreal Clindamycin was administered twice and patient could be treated successfully though a surgical management had to be added to the management plan because of the development of a rhegmatogenous retinal detachment.<sup>23</sup>

**Punctate outer retinal toxoplasmosis (PORT):** These are multifocal grey white small punctate lesions mostly occurring at macula seen in the outer layers of the neuro-sensory retina and retinal pigment epithelium. Since not involving the inner layers, there is minimal vitritis if any. Souza and Casella in their small case series of five patients, demonstrate ocular tomographic features of these lesions in five patients in whom the diagnosis of OT was supported by raised serum levels of anti-toxoplasma IgG and IgM antibodies and favorable response to anti-parasitic therapy.<sup>24</sup> After resolving, these lesions might form fine granular white dots.<sup>25</sup> It is important to identify these lesions as atypical OT as these mostly resolve with complete recovery of vision with appropriate therapy. Lujan also reports a case with interesting tomographical changes in the subretinal fluid space present at the initial visit, over three follow up visits in a patient with PORT.<sup>26</sup> Multimodal imaging of these lesions might be the way forward for establishing diagnosis and monitoring treatment response in these cases.<sup>27</sup>

**Optic nerve involvement:** Optic nerve involvement can occur in varied forms in OT [Figure 3]. An ophthalmologist needs to be aware of these forms to diagnose OT in a case coming with optic nerve involvement to differentiate it from other optic nerve diseases and start appropriate treatment as the visual prognosis in most of these cases is encouraging.

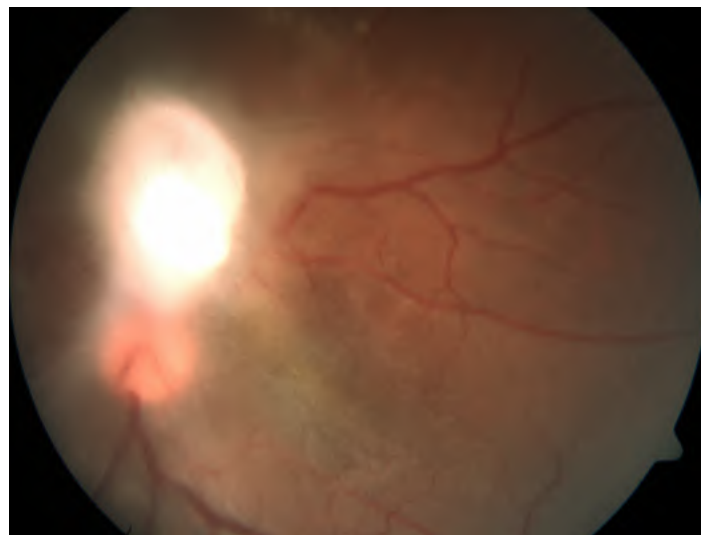


Figure 3

Eckert and associates (2007) in their study of 926 patients visiting uveitis department with active OT in a Brazilian hospital found the prevalence of optic nerve changes to be 5.3% (51 eyes of 49 patients). The most frequent presentation was the presence of a swollen optic disc with a concomitant distant active retino-choroiditis lesion (43.1%). Swollen optic disc along with a juxtapapillary lesion was the next most common presentation (35.3%). It had a dramatic presentation with numerous associated exudates, hemorrhages and reduced visual acuity but improved rapidly with treatment. Direct involvement of optic nerve was almost negligible; there were 3 (5.9%) cases of pure papillitis and no cases of isolated neuroretinitis. Mixed type of involvement with one or more of these four lesions was seen in 15.7% eyes. The involvement was unilateral in 95.9% patients.<sup>28</sup>

In another case series of 154 OT patients done at an institute in the Netherlands, papillitis was found in 13% of OT patients<sup>9</sup>. Atmaca et al in their retrospective study, found papillitis in 2 (3%) eyes and neuroretinitis in 4 (6%) eyes amongst 65 eyes with active lesions at time of presentation.<sup>29</sup>

Neuroretinitis was the second most frequent atypical presentation of OT reported in the ophthalmologist-based survey done at Hyderabad.<sup>11</sup> Neuroretinitis is characterized by moderate-to-severe loss of vision, optic disc edema, macular star and serous macular detachment at the macula. It can be idiopathic, post-viral or due to other infective causes. Vitreous inflammation, presence of toxoplasma scar and positive serology may give a clue to the diagnosis in *Toxoplasma* neuroretinitis. Optic nerve atrophy (4%) might occur as a complication of OT.<sup>9</sup>

**Various retinal detachments:** In a retrospective study with records of 150 patients of OT, Driessen et al found that the prevalence of retinal detachment (RD) was 6% (n=9). These patients were more frequently myopic than the group which did not have an RD and they had had a severe vitritis preceding the RD.<sup>30</sup> The visual prognosis of these patients might remain poor despite treatment.<sup>30,31</sup> The retinal detachment in OT can be tractional, rhegmatogenous or exudative.<sup>32,33</sup> There is a rare interesting case report of a healthy 30-year-old female presenting with a subretinal macrocyst with rhegmatogenous RD (RRD) and multiple retinal breaks in the inferior quadrant. As no active lesions were seen in fundus and the hyperpigmented lesions surrounding retinal breaks were thought to be associated with long-standing RRD, initial differentials considered were subretinal hydatid cyst, sub-retinal cysticercus cyst and metastatic tumours. After a negative diagnostic work-up for these differentials, the patient underwent a vitrectomy, cystotomy and complete excision of cyst along with the overlying retina. Subsequent histopathologic examination, PCR analysis and serologic tests confirmed the diagnosis of intra-ocular *Toxoplasma gondii* infection.<sup>34</sup>

**Atypical pigmentary retinopathy:** Pigmentary retinopathy can occur due to the inflammation induced in these cases and should be differentiated from retinitis pigmentosa. In OT, it will more commonly be unilateral and involving only a portion of fundus.<sup>35</sup> Syphilis or rubella infection can be the differential diagnosis.

**Retinal peri-phlebitis and vasculitis:** Active *Toxoplasma* lesions may be associated with a nearby or distant vasculitis which is characterised by an exudation around the involved vessels. Prevalence of vascular sheathing in active disease can be as high as 72%<sup>32</sup>. Arteries are commonly involved [Figure 4].<sup>36</sup> Vasculitis is frequently present in the same quadrant as the retino-choroiditis lesion in active disease.<sup>37</sup> Vascular occlusion has also been known to occur in cases where there is dense vascular infiltration of vessels, especially in cases where the vessel crosses over the active retinal lesion.<sup>37-40</sup> The disease evolves in many cases; vascular involvement might encroach the same vessel along its further course or adjacent vessels.

Figure 4: Retinal arterial involvement in a healed toxoplasma lesion more often described as kyrieleis arteriitis.

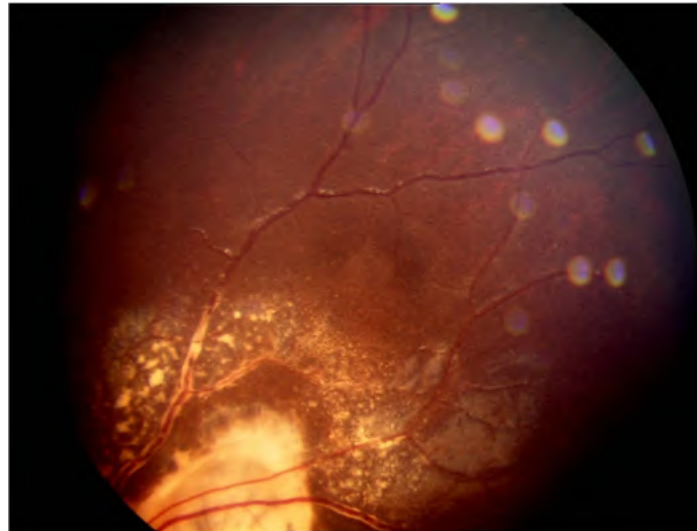


Figure 4

Retinal neovascularisation though rare, has been reported where vascular occlusion of a blood vessel crossing a scar lead to capillary non-perfusion and subsequently, adjacent neovascularisation and vitreous haemorrhage. These eyes can improve with photocoagulation of the ischemic area.<sup>40</sup> Sub-retinal neovascularisation has also been reported in handful of cases<sup>41</sup>. Lafaut et al showed presence of vasoproliferative retinal tumour in 8 eyes with presumed congenital toxoplasmosis. These lesions were present in or adjacent to complex chorioretinal scars and these scars were vascularised by choroidal vessels as demonstrated by angiographic studies.<sup>42</sup> Diaz Valle et al reported a rare case in which OT was diagnosed in a case with frosted branch angiitis but no accompanying retinochoroidal scar. At a one year follow-up visit, retinochoroidal scar was seen in the periphery.<sup>43</sup>

**Ischemia of choroid:** This can also be an unusual feature in OT.<sup>44-46</sup> In a case reported by Panos et al where there was an active OT lesion as well as a hole, they demonstrated choroidal ischemia in the area of the active lesion with tomographic, angiographic and flowmetry studies and postulated that it could have lead to the full-thickness macular hole in this patient. Blaise et al had first reported a case with a giant macular hole in a patient with a history of acquired toxoplasmosis 7 years back.<sup>47</sup>

Some other vitreoretinal entities that can lead to vision loss in patients with ocular toxoplasmosis are persistent vitreous opacities/ activity (21%), cystoid macular edema (13%), pre-retinal membranes (7%) and vitreous haemorrhage (2%).<sup>9</sup>

**Scleral inflammation:** Cases of scleritis with active toxoplasma retinitis have been rarely reported in literature in immunosuppressed individuals, immune-competent individuals and during pregnancy as well.<sup>48-50</sup> The disease can get as severe as one requiring enucleation if appropriate treatment is not instituted.<sup>49</sup>

**Complex course:** Other complications apart from those already described include cataract formation, uveitic glaucoma, posterior synechiae, Phthisis bulbi and Pars Plana detachment. Central nervous system involvement can be seen in atypical case [Figure 5].

Figure 5: Computed tomography of brain showing an active focus of toxoplasma lesion (Marked with arrow). Patient presented with right fundus toxoplasma lesion with symptoms of seizures.

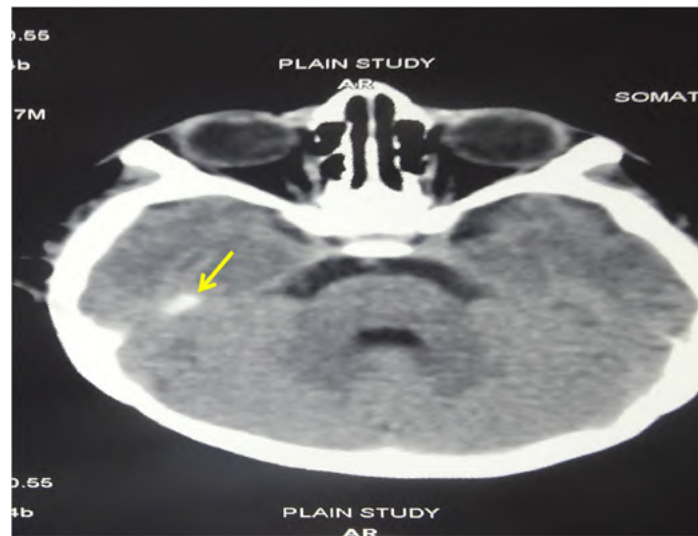

Figure 5

Complication rate as 13.47% in a study done by Kianersi et al,<sup>32</sup> 44% in the study by Bosch Dreissen et al<sup>9</sup> and 34.8% in a study done by Kim et al.<sup>33</sup>

Clinical diagnosis can be the sole means of making a diagnosis in a classical presentation. But in atypical presentations, laboratory investigations can be of great value in arriving at a diagnosis. Laboratory tests useful for diagnosis include 1. Detection of local antibody production by testing of Toxoplasma-specific intra-ocular antibodies in intra-ocular fluids by immunoblotting or determination of Goldman Witmer coefficient. 2. PCR analysis of ocular fluid for the presence of Toxoplasma DNA. A combination of two or three of these further improves diagnostic yield.<sup>51-54</sup>

Holland emphasizes that the atypical forms of disease are just uncommon presentations of the same disease process whereby infection of retinal tissue incites an immune response. And the study of different characteristics of the disease can help us develop a better understanding of disease mechanisms.<sup>12</sup>

## References:

1. Furtado JM, Winthrop KL, Butler NJ, Smith JR: Ocular toxoplasmosis I: Parasitology, epidemiology and public health. *Clin Exp Ophthalmol*. 2013; 41(1):82-94.
2. Dogra M, Singh R, Agarwal A, Sharma A, Singh SR, Gautam N et al. Epidemiology of uveitis in a tertiary-care referral institute in North India. *Ocul Immunol Inflamm*. 2017;25:S46–53.
3. Lodhi SA, Reddy SG, Maryam A. Pattern of posterior uveitis in a tertiary care government eye hospital in South India. *J Clin Ophthalmol Res* 2017;5:73-6.



4. Biswas J, Kharel Sitaula R, Multani P. Changing uveitis patterns in South India-Comparison between two decades. *Indian J Ophthalmol*. 2018; 66(4):524–527.
5. Rathinam S R, Namperumalsamy P. Global variation and pattern changes in epidemiology of uveitis. *Indian J Ophthalmol* 2007;55:173-83
6. Das D, Bhattacharjee H, Bhattacharyya PK, Jain L, Panicker M J, Das K, Deka AC. Pattern of uveitis in North East India: A tertiary eye care center study. *Indian J Ophthalmol* 2009;57:144-6
7. Palsule AC, Jande V, Kulkarni AA, Beke NN. Pattern of uveitis in a tertiary eye care center in Western India. *J Clin Ophthalmol Res* 2017;5:127-31
8. Singh R, Gupta V, Gupta A. Pattern of uveitis in a referral eye clinic in north India. *Indian J Ophthalmol* 2004;52:121-5.
9. Bosch-Driessen LE, Berendschot TT, Ongkosuwito JV, Rothova A. Ocular toxoplasmosis: clinical features and prognosis of 154 patients. *Ophthalmology* 2002; 109:869–78.
10. Borkowski PK. New trends in ocular toxoplasmosis—the review. *Przegl Epidemiol*. 2001;55(4): 483-93.
11. Basu S, Biswas J, Pleyer U, Pathangay A, Manohar Babu B. An ophthalmologist survey-based study of the atypical presentations and current treatment practices of ocular toxoplasmosis in India. *J Parasit Dis*. 2011;35(2):148–154.
12. Holland GN. Ocular toxoplasmosis: a global reassessment. Part II: disease manifestations and management. *Am J Ophthalmol*. 2004;137(1):1-17.
13. Labalette P, Delhaes L, Margaron F, Fortier B, Rouland JF. Ocular toxoplasmosis after the fifth decade. *Am J Ophthalmol* 2002, 133:506–515.
14. Johnson MW, Greven GM, Jaffe GJ, Sudhalkar H, Vine AK. Atypical, severe toxoplasmic retinochoroiditis in elderly patients. *Ophthalmology*. 1997 Jan;104(1):48-57.
15. Errera MH, Chahed S, Man H, Garin YJ, Bergmann JF, Gaudric A, Massin P. Severe disseminated toxoplasmosis with atypical chorioretinitis. A case of primary infection. *J Fr Ophtalmol*. 2009 May;32(5):348.e1-5.
16. Cochereau-Massin I, LeHoang P, Lautier-Frau M, et al: Ocular toxoplasmosis in human immunodeficiency virus-infected patients. *Am J Ophthalmol* 1992, 114:130–135.
17. Holland GN, Engstrom RE Jr, Glasgow BJ, Berger BB, Daniels SA, Sidikaro Y et al. Ocular toxoplasmosis in patients with the acquired immunodeficiency syndrome. *Am J Ophthalmol* 1988, 106:653–667.
18. Gagliuso DJ, Teich SA, Friedman AH, Orellana J. Ocular toxoplasmosis in AIDS patients. *Trans Am Ophthalmol Soc*. 1990;88:63–88.

19. Hasselbach HC, Fickenscher H, Nolle B, Roeder J. Atypical ocular toxoplasmosis with concomitant ocular reactivation of varicella-zoster virus and cytomegalovirus in an immunocompromised host. *Klin Monbl Augenheilkd.* 2008 Mar;225(3):236-9.
20. Moorthy RS, Smith RE, Rao NA: Progressive ocular toxoplasmosis in patients with acquired immunodeficiency syndrome. *Am J Ophthalmol* 1993, 115:742–747.21.
21. B Balansard, B Bodaghi, N Cassoux, C Fardeau, S Romand, F Rozenberg et al. Necrotising retinopathies simulating acute retinal necrosis syndrome. *Br J Ophthalmol* 2005; 89: 96–101.
22. Elkins BS, Holland GN, Opremcak EM, Dunn JP Jr, Jabs DA, Johnston WH et al. Ocular toxoplasmosis misdiagnosed as cytomegalovirus retinopathy in immunocompromised patients. *Ophthalmology* 1994;101:499–507.23.
23. Yusuf IH, Izadi S, Fung TH, Sallam A, Patel CK. Multifocal necrotizing chorioretinitis following phacoemulsification surgery. *Ocul Immunol Inflamm.* 2015 Jun;23(3):261-5.
24. de Souza EC, Casella AMB. Clinical and Tomographic Features of Macular Punctate Outer Retinal Toxoplasmosis. *Arch Ophthalmol.* 2009;127(10):1390–1394.
25. Doft BH, Gass DM: Punctate outer retinal toxoplasmosis. *Arch Ophthalmol* 1985, 103:1332–1336.
26. Lujan BJ. Spectral domain optical coherence tomography imaging of punctate outer retinal toxoplasmosis. *Saudi J Ophthalmol.* 2014;28(2):152–156.
27. Yannuzzi NA, Gal-Or O, Motulsky E, Swaminathan SS, Cunningham ET Jr, Davis JL et al. Multimodal Imaging of Punctate Outer Retinal Toxoplasmosis. *Ophthalmic Surg Lasers Imaging Retina.* 2019 May 1;50(5):281-287
28. Eckert GU, Melamed J, Menegaz B. Optic nerve changes in ocular toxoplasmosis. *Eye (Lond).* 2007 Jun;21(6):746-51.
29. Atmaca LS, Simsek T, Batioglu F. Clinical features and prognosis in ocular toxoplasmosis. *Jpn J Ophthalmol.* 2004 Jul-Aug;48(4):386-91.
30. Bosch-Driessen LH, Karimi S, Stilma JS, Rothova A. Retinal detachment in ocular toxoplasmosis. *Ophthalmology.* 2000 Jan;107(1):36-40.
31. Faridi A, Yeh S, Suhler EB, Smith JR, Flaxel CJ. Retinal detachment associated with ocular toxoplasmosis. *Retina.* 2015 Feb;35(2):358-63.
32. Farzan Kianersi , Afsaneh Naderi Beni, Zahra Naderi Beni. Clinical manifestation and prognosis of active ocular toxoplasmosis in Iran. *Int Ophthalmol* (2012) 32:539–545.
33. Kim M, Choi SY, Won JY, Park YH. Patterns of ocular toxoplasmosis presenting at a tertiary eye care center in Korean patients. *Medicine (Baltimore).* 2018;97(15):e0399.

34. Karimi S, Nikkhah H, Fekri S. Ocular toxoplasmosis presenting as subretinal macrocyst. *J Ophthalmic Vis Res* 2019;14:223-5.
35. Silveira C, Belfort R Jr, Nussenblatt R, Unilateral pigmentary retinopathy associated with ocular toxoplasmosis. *Am J Ophthalmol* 1989, 107:682–684.
36. Abu El-Asrar, A. M., Herbort, C. P, Tabbara, K. F. Differential diagnosis of retinal vasculitis. *Middle East African journal of ophthalmology*. 2009 Oct-Dec; 16(4): 202–218.
37. Theodossiadis P, Kokolakis S, Ladas I, Kollia AC, Chatzoulis D, Theodossiadis G. Retinal vascular involvement in acute toxoplasmic retinochoroiditis. *Int Ophthalmol* 1995, 19:19–24.
38. Braunstein RA, Gass JD. Branch artery obstruction caused by acute toxoplasmosis. *Arch Ophthalmol* 1980, 98:512–513.
39. Morgan CM, Gragoudas ES. Branch retinal artery occlusion associated with recurrent toxoplasmic retinochoroiditis. *Arch Ophthalmol* 1987, 105:130–131.
40. Gaynon MW, Boldrey EE, Strahlman ER, Fine SL. Retinal neovascularization and ocular toxoplasmosis. *Am J Ophthalmol* 1984, 98:585–589.
41. Cotliar AM, Friedman AH: Subretinal neovascularization in ocular toxoplasmosis. *Br J Ophthalmol* 1982, 66:524–529.
42. Lafaut BA, Meire FM, Leys AM, Dralands G, De Laey JJ. Vasoproliferative retinal tumors associated with peripheral chorioretinal scars in presumed congenital toxoplasmosis. *Graefes Arch Clin Exp Ophthalmol* 1999, 237:1033–1038.
43. Diaz-Valle D, Diaz-Rodriguez E, Diaz-Valle T, Benítez del Castillo JM, Toledano N, Fernández Aceñero MJ. Frosted branch angiitis and late peripheral retinochoroidal scar in a patient with acquired toxoplasmosis. *Eur J Ophthalmol*. 2003;13:726–8.
44. Al-Zahrani YA, Al-Dhibi HA, Al-Abdullah AA. Atypical Presentation of Ocular Toxoplasmosis: A Case Report of Exudative Retinal Detachment and Choroidal Ischemia. *Middle East Afr J Ophthalmol*. 2016;23(1):150–152.
45. Khairallah M, Yahia SB, Zaouali S, Jenzeri S, Attia S, Messaoud R. Acute choroidal ischemia associated with toxoplasmic retinochoroiditis. *Retina*. 2007 Sep;27(7):947-51.
46. Panos GD, Papageorgiou E, Kozeis N, Gatzoufas Z. Macular hole formation after toxoplasmic retinochoroiditis. *BMJ Case Rep*. 2013; 2013: bcr2013008915.
47. Blaise P, Comhaire Y, Rakic JM. Giant macular hole as an atypical consequence of a toxoplasmic chorioretinitis.. *Arch Ophthalmol*. 2005; 123(6):863-4.
48. Kamath YS, Rathinam S R, Kawali A. Ocular toxoplasmosis associated with scleritis. *Indian J Ophthalmol* 2013; 61:295-7.

49. Schuman JS, Weinberg RS, Ferry AP, Guerry RK. Toxoplasmic scleritis. *Ophthalmology*. 1988;95:1399–403.
50. Rudich DS, Bhatnagar P. Scleritis Associated With Toxoplasmic Retinochoroiditis. *Arch Ophthalmol*. 2012; 130(5):659–660.
51. Garweg JG, de Groot-Mijnes JDF, Montoya JG. Diagnostic approach to ocular toxoplasmosis. *Ocul Immunol Inflamm*. 2011; 19(4):255–261.
52. Fekkar A, Bodaghi B, Touafek F, Le Hoang P, Mazier D, Paris L. Comparison of immunoblotting, calculation of the Goldmann-Witmer coefficient, and real-time PCR using aqueous humor samples for diagnosis of ocular toxoplasmosis. *J Clin Microbiol*. 2008; 46(6):1965–1967.
53. Villard O, Filisetti D, Roch-Deries F, Garweg J, Flament J, Candolfi E. Comparison of enzyme-linked immunosorbent assay, immunoblotting, and PCR for diagnosis of toxoplasmic chorioretinitis. *J Clin Microbiol*. 2003; 41(8):3537–3541.
54. Fardeau C, Romand S, Rao NA, Cassoux N, Bettembourg O, Thulliez P et al. Diagnosis of toxoplasmic retinochoroiditis with atypical clinical features. *Am J Ophthalmol* 2002; 134:196–203.



# **Constellation of clinical trials done on Ocular toxoplasmosis**

Author:

Dr. Bharat Gurnani

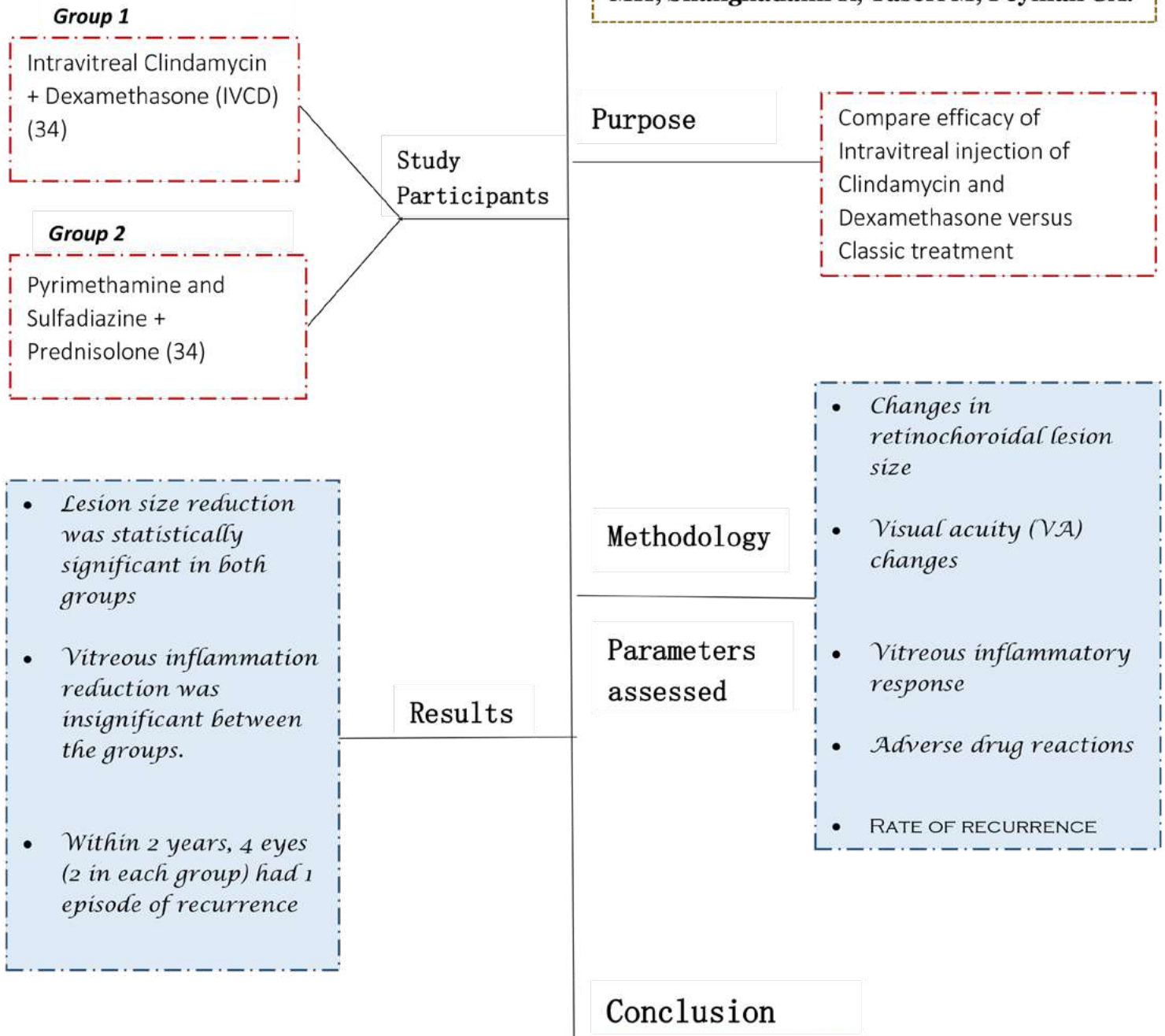
Dr. Kiran Deep Kaur

Dr. Pranesh Bala Subramaniam

Dr. S Bala Murgan

Randomized trial of intravitreal clindamycin and dexamethasone versus pyrimethamine, sulfadiazine, and prednisolone in treatment of Ocular toxoplasmosis.

Soheilian M1, Ramezani A, Azimzadeh A, Sadoughi MM, Dehghan MH, Shahghadami R, Yaseri M, Peyman GA.



IVCD may be an acceptable alternative to the CT in ocular toxoplasmosis.

## Fulminant Ocular Toxoplasmosis : The Hazards of Corticosteroid Monotherapy.

**Oray M, Ozdal PC, Cebeci Z, Kir N, Tugal-Tutkun I**

### Purpose

To describe fulminant toxoplasma retinochoroiditis induced by corticosteroid monotherapy

### Study Participants

Clinical records of 9 patients were reviewed

### Methodology

- Mean disease duration before referral [  $105.6 \pm 71$  (45-240) days]

### Parameters assessed

- Visual acuity at presentation [ $<20/200$  in 6 eyes]
- Mean duration of anti-toxoplasmic therapy [  $92.5 \pm 37.1$  days]

### Results

- 3 eyes developed RRD
- 4 patients underwent PPV
- Final visual acuity  $<20/200$  in 5 eyes

### Conclusion

Iatrogenic immunosuppression due to initial misdiagnosis may lead to an aggressive course and serious complications of ocular toxoplasmosis, a potentially self-limiting infection.

# Antibiotics for toxoplasmic retinochoroiditis: an evidence-based systematic review.

Stanford MR, See SE, Jones LV, Gilbert RE

## Purpose

To determine the effectiveness of systemic antibiotic treatment

## Study Participants

3 randomized controlled trials  
(173 participants)

## Methodology

Randomized Controlled Trials

## Results

- *None trials reported effect on long-term visual outcome*
- *No evidence of beneficial effect on the duration and severity of signs of acute toxoplasmic retinochoroiditis*
- *Weak evidence for an effect of long-term treatment for chronic recurrent toxoplasmic retinochoroiditis on lesion recurrence*

## Conclusion

Placebo-controlled randomized trials of antibiotic treatment in patients with acute or chronic toxoplasmic retinochoroiditis arising in any part of the retina are required



**Spectral optical coherence tomography findings in patients with ocular toxo plasmosis and active satellite lesions (MINAS Report 1)**

**Oréface JL<sup>1</sup>, Costa RA, Scott IU, Calucci D, Oréface F; Grupo Mineiro de Pesquisa em Doenças Oculares Inflamatórias**

**Study Participants**

24 patients with OT and satellite lesions

- Mean age = 27.6 years
- The mean LogMAR ETDRS BCVA was 0.58
- Posterior hyaloid was diffusely thickened in 95.8% eyes, increased Vitreous hyper-reflective signals 75.0%, vitreal spherical hyper-reflective depositions in 50.0% eyes
- All patients, the inner retinal layers were abnormally hyper-reflective + full-thickness disorganization of the retinal layers associated choriocapillaris/ choroidal optical shadowing 91.7% eyes.

**Results**

**Purpose**

To characterize the active retinochoroiditis lesion in patients with the classic clinical presentation utilizing spectral optical coherence tomography (SOCT)

**Methodology**

Standardized ophthalmologic examination and multimodal fundus imaging

**Conclusion**

Full-thickness disorganization of the retinal reflective layers, generally associated with some degree of posterior optical shadowing, was observed in the active OT lesion in all patients  
The posterior hyaloid was often thickened and, adjacent to the OT lesion, the outer retina was consistently altered

## Treatment Of Toxoplasma Uveitis With Pyrimethamine.

E. S. Perkins, C. H. Smith, P. B. Schofield

### Purpose

To compare Pyrimethamine versus Placebo for Toxoplasmosis treatment

### Methodology

- ❖ *Double masked RCT*
- ❖ *Visual acuity*
- ❖ *Improvement in symptoms*
- ❖ *Degree of injection*
- ❖ *Aqueous flare, vitreous flare*

### Parameters assessed

### Study Participants

#### Group 1

Pyrimethamine (56)

#### Group 2

Placebo (42)

Positive Toxoplasma Reaction

### Results

- *Group 1 - 76% patients improved*
- *Group 2 - only 50 % improved*

### Conclusion

76% patients with a positive toxoplasma reaction who received treatment with pyrimethamine improved against 50 % of the control group

## Toxoplasmic Retinochoroiditis: A Double Blind Therapeutic Study

Thomas E. Acers, Md, Lawton, Okla

### Group 1

Pyrimethamine,  
Trisulfapyrimidines,  
and Prednisone (10)

### Group 2

Oral Prednisone (10)

Study  
Participants

Purpose

To compare therapeutic efficacy of triple therapy versus oral corticosteroids alone

Methodology

- ❖ *Randomized, placebo-controlled, and double-masked*
- *Active retinitis, usually with overlying posterior vitreous opacities*

Inclusion  
Criteria

- *Positive intradermal toxoplasmin skin test*
- *Positive Sabin méthylène blue dye test*
- *Lack of significant clinical or laboratory evidence for any other etiology for the granulomatous focal type of retinochoroiditis*

Results

- *All the patients showed progressive improvement with clearing of the vitreous and partial subsidence of the retinitis by 3 weeks and almost complete clearing by 8 weeks*
- *There was no significant difference between the 2 therapeutic groups as to time of quiescence of the lesion*

Conclusion

Isolated steroid therapy alone is as efficacious as triple therapy

## Prospective Randomized Trial of Trimethoprim/Sulfamethoxazole versus Pyrimethamine and Sulfadiazine in the Treatment of Ocular Toxoplasmosis

Masoud Soheilian et al

### Group 1

Classic therapy with Pyrimethamine, Sulfadiazine, and Folinic acid + Oral steroids (29)

Study Participants

### Group 2

Trimethoprim/Sulfamethoxazole + Oral steroids (30)

Active Ocular Toxoplasmosis

### Purpose

To compare the efficacy of the Classic treatment with Trimethoprim/Sulfamethoxazole (Co-trimoxazole) plus Prednisolone

### Methodology

- ❖ *Controlled, randomized, single-blind fashion*
- ❖ *Inclusion Criteria -*
  - *Presence of visual complaints and an area of focal necrotizing retinochoroidal lesion*
- ❖ *Outcome Measures -*
  - *Lesion size reduction (primary)*
  - *VA, vitreous inflammation, adverse drug reaction, and recurrence rate (secondary)*

### Results

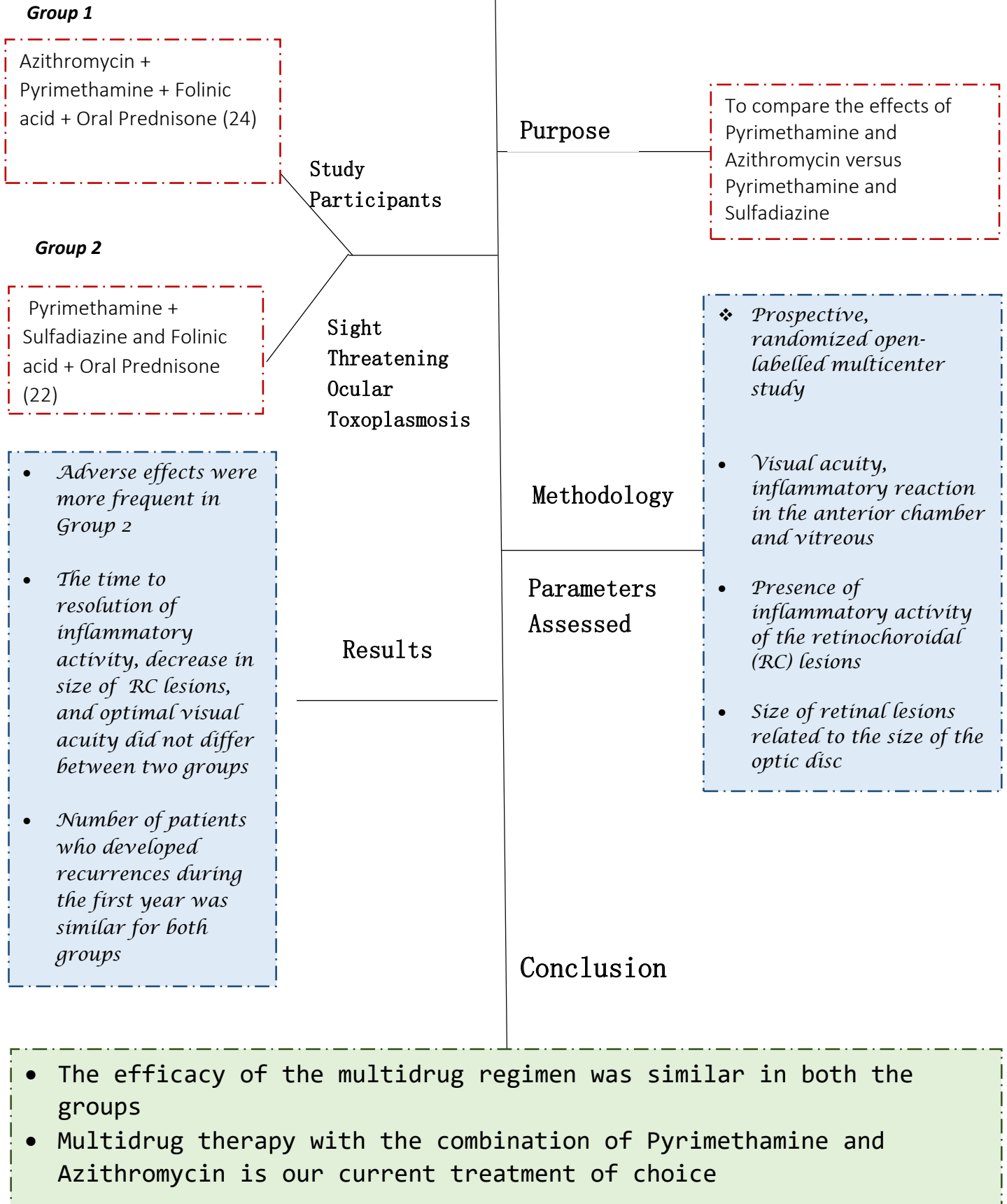
- *There was no statistically significant difference in visual improvement between both the groups*
- *There was no significant difference between the 2 treatment groups in terms of reduction in retinal lesion size*
- *There was also an insignificant difference in reduction of vitreous inflammation between groups*

### Conclusion

Trimethoprim/sulfamethoxazole is an alternative to classic treatment, with greater availability, less cost, and a safer drug profile in immunocompetent patients

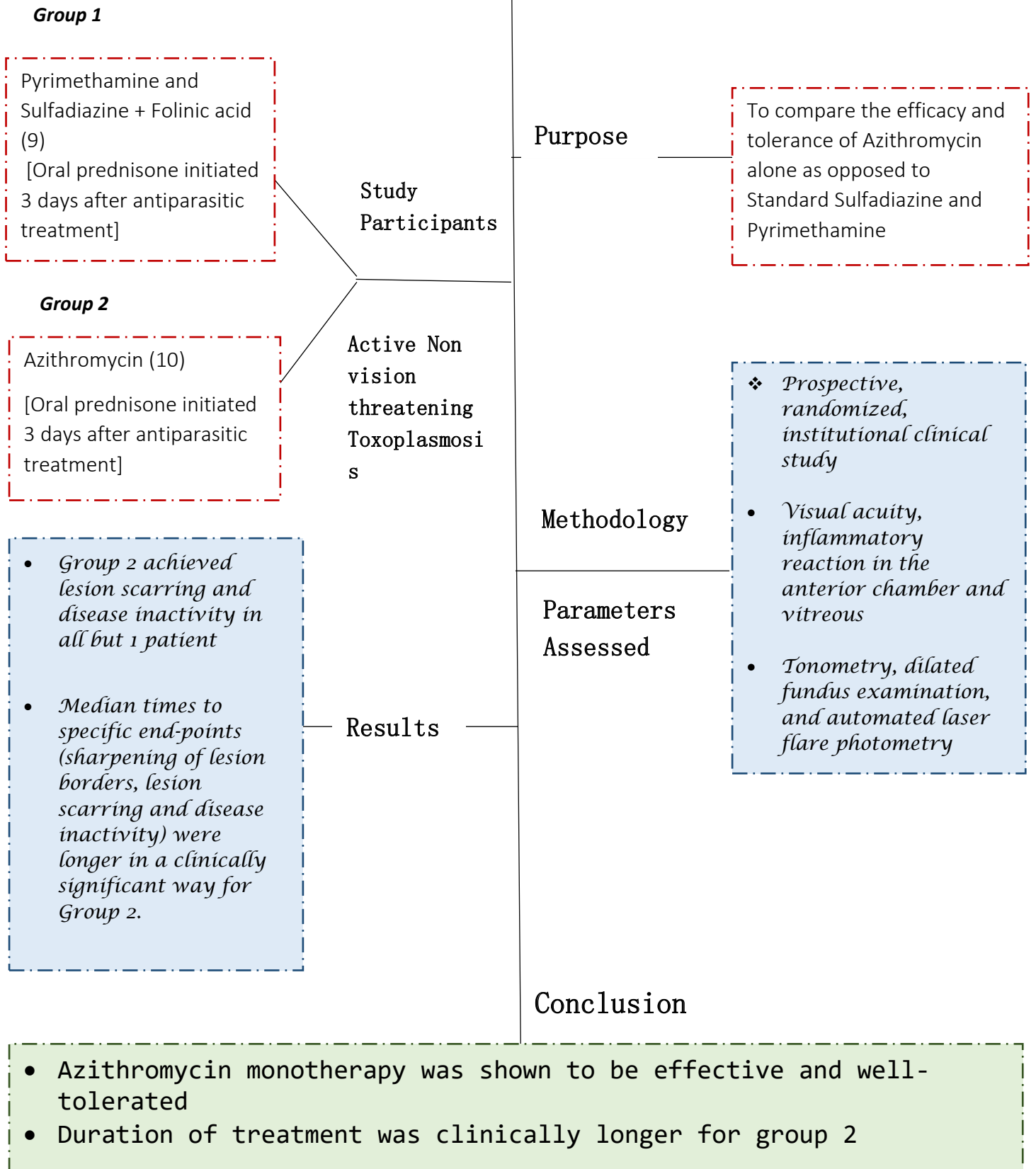
## Prospective, Randomized Trial of Pyrimethamine and Azithromycin Vs Pyrimethamine and Sulfadiazine for the Treatment of Ocular Toxoplasmosis

Lotje H. Bosch-Driessen et al



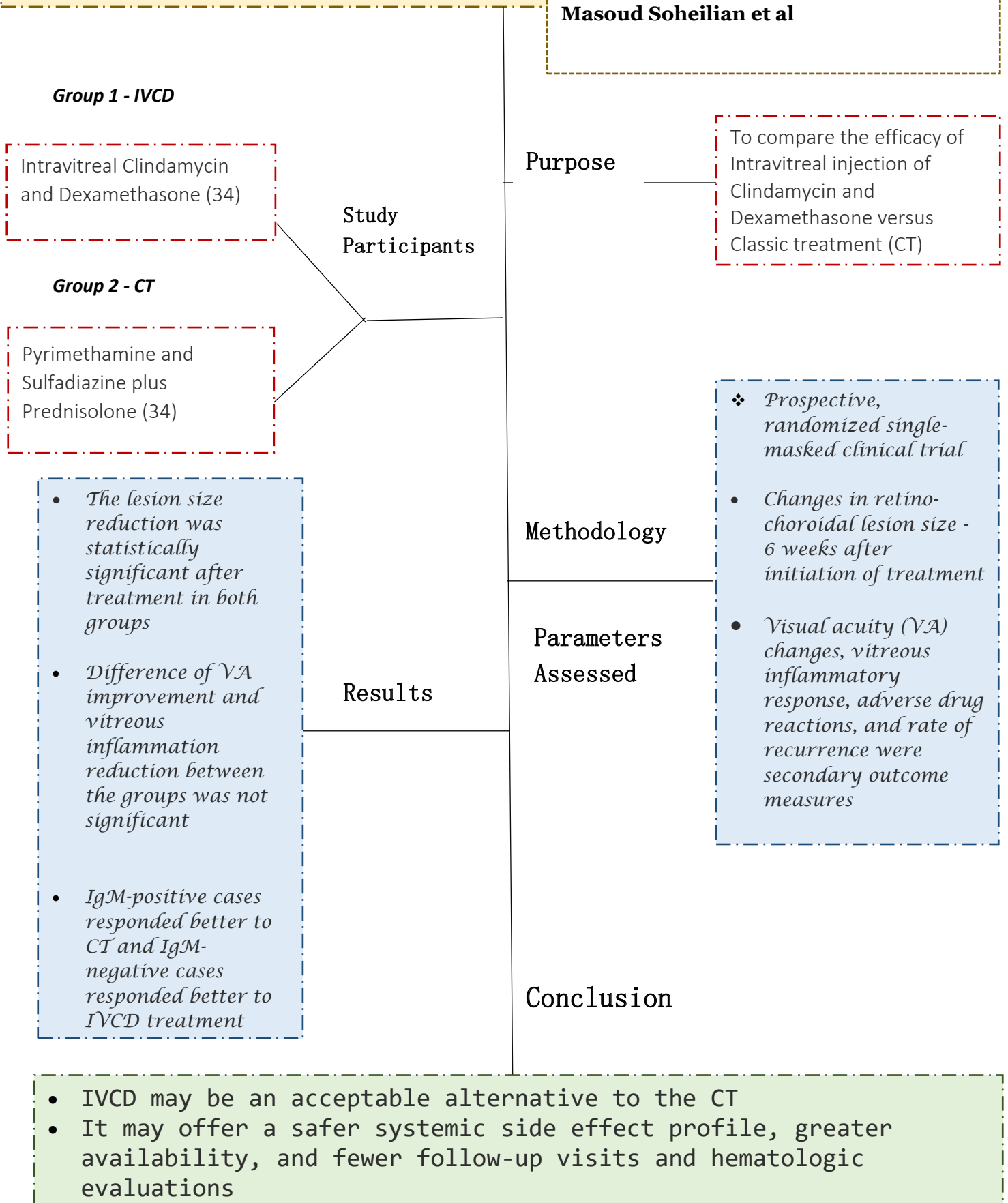
# Azithromycin versus Sulfadiazine and Pyrimethamine for non-vision threatening toxoplasmic retinochoroiditis: A pilot study

Konstantinos Balaskas et al



## Randomized Trial of Intravitreal Clindamycin and Dexamethasone versus Pyrimethamine, Sulfadiazine, and Prednisolone in Treatment of Ocular Toxoplasmosis

**Masoud Soheilian et al**



# The effect of long-term intermittent trimethoprim /sulfamethoxazole treatment on recurrences of toxoplasmic retinochoroiditis

**Claudio Silveira, MD, Rubens Belfort, JR**

## Group 1

Trimethoprim and Sulfamethoxazole every 3 days/week for up to 20 months (61)

## Group 2

Control group (63)

### Study Participants

### Purpose

To determine the effect of long-term intermittent Trimethoprim/Sulfamethoxazole treatment on recurrences of toxoplasmic retinochoroiditis

### Methodology

*Prospective randomized open-labelled interventional clinical trial*

- *Recurrent toxoplasmic retinochoroiditis, defined clinically as a new focus of retinal inflammation either adjacent to or remote from preexisting retinochoroidal scars*
- *Recurrent disease in either eye was considered a recurrence for study purposes*

### Results

- *Among subjects in group 1, recurrent toxoplasmic retinochoroiditis developed in four patients- 6%*
- *Among patients in group 2, recurrent toxoplasmic retinochoroiditis developed in 15 patients - 23.8%*

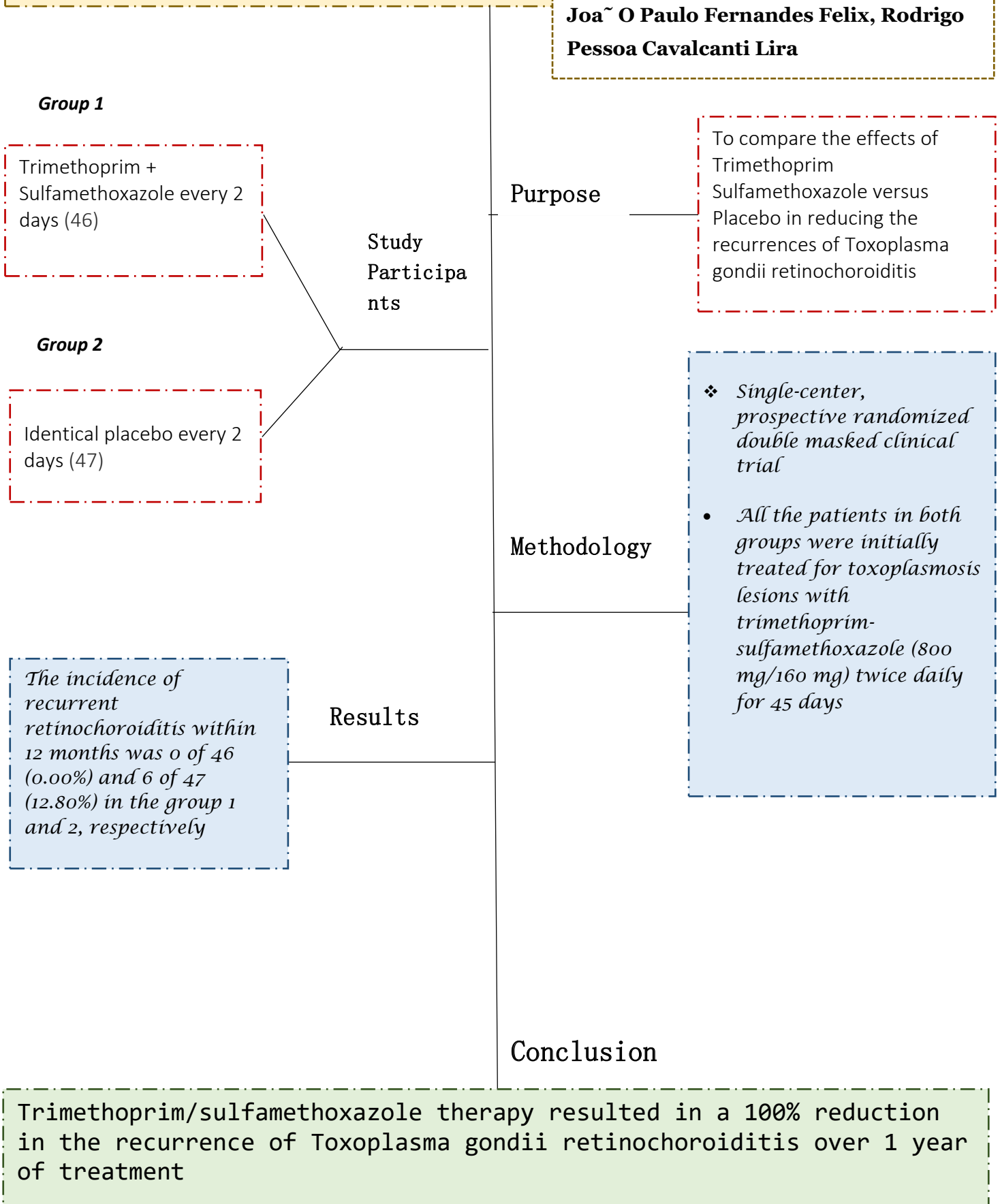
### Conclusion

Long-term intermittent treatment with trimethoprim/sulfamethoxazole can reduce the rate of recurrent toxoplasmic retinochoroiditis



# Trimethoprim-Sulfamethoxazole Versus Placebo to Reduce the Risk of Recurrences of Toxoplasma Gondii Retinochoroiditis: Randomized Controlled Clinical Trial

Joa~ O Paulo Fernandes Felix, Rodrigo Pessoa Cavalcanti Lira



## Prophylactic Photocoagulation of Recurrent Toxoplasmic Retinochoroiditis

Harold F. Spalter, Md; Charles J. Campbell

### Purpose

To evaluate the effects of photocoagulation on the prevention of recurrences

### Study Participants

History of recurrent Toxoplasma Retinochoroiditis (24)

### Methodology

- Probable diagnosis of Toxoplasmic Retinochoroiditis
- At least one active recurrence at the site of the lesion

### Selection Criteria

- ❖ Laboratory criteria for a probable diagnosis
  - A positive dye test titre (Sabin-Feldman) of 1:16 or greater
  - Positive toxoplasmin skin test

### Results

- None of the patients developed recurrent retinitis in the photocoagulated areas during a 6- to 33-months follow-up period
- 2 recurrences in the area distal to the photocoagulated areas
- ❖ No complications were encountered as a result of laser coagulation

### Conclusion

Photocoagulation helps in preventing recurrence of retinitis in toxoplasmosis

# Treatment of Toxoplasma Uveitis.

Romeo V. Fajardo, M.D.; Francis P. Furgiuele, M.D

**Group 1**  
Pyrimethamine and Sulfa (40)

**Group 2**  
Spiramycin (41)

**Group 3**  
Steroids Alone (6)

Study Participants

## Purpose

To compare the efficacy of

1. Pyrimethamine and Sulfa
2. Spiramycin
3. Steroids Alone

## Methodology

- *Retrospective analysis*
- *Chorioretinal lesion with necrosis with or without an adjacent old scar*
- *Vitreous reaction that shows new cells biomicroscopically*
- *Positive skin test to toxoplasmin redness*
- *Positive Sabin Feldman dye test*
- *Satisfactory elimination of other known conventional causes of uveitis*

## Inclusion Criteria

## Results

- *Group 1 showed the best results. The uveitis became inactive much earlier, and more cases healed during the first 8 weeks compared to others*
- *Prior use of systemic steroids in the group 1 did not alter the onset of healing*
- *Group 2 cases healed 4 weeks later if steroids were given prior to the specific therapy*

## Conclusion

- The combination of pyrimethamine, sulfa drugs, and steroids is far more effective treatment of toxoplasmosis uveitis than spiramycin and steroids or steroids alone.
- Systemic steroids enhances the therapeutic effectiveness of pyrimethamine and sulfa.



# **Primary acquired Toxoplasma Retinochoroiditis: Clinical Response and Swept-source What is new in the imaging of ocular toxoplasmosis?**

**Author:**

**Dr. Abhilasha Baharani**

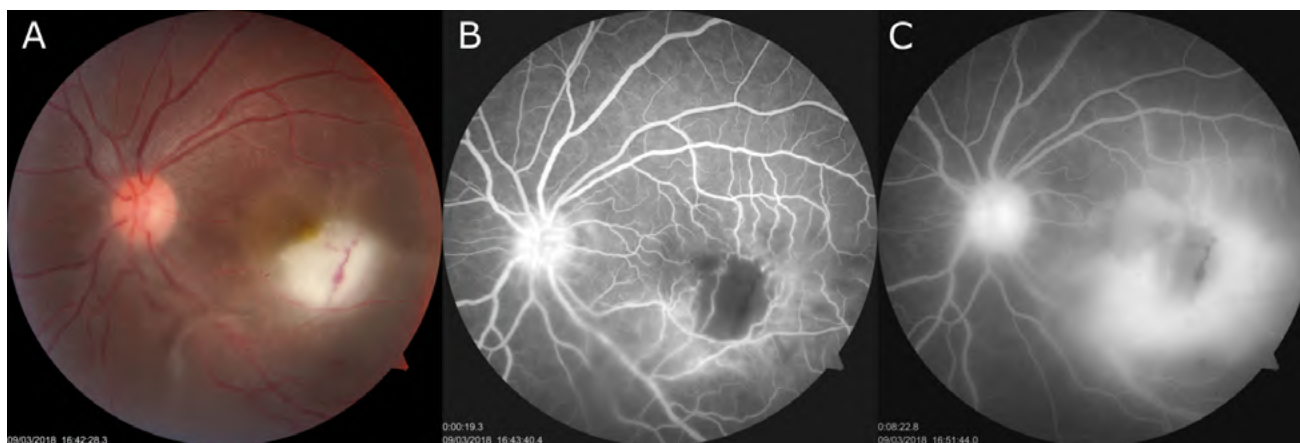
## Primary acquired Toxoplasma Retinochoroiditis: Clinical Response and Swept-source What is new in the imaging of ocular toxoplasmosis?

**Abhilasha Baharani**, DNB FRCS FICO,

Consultant Uvea Specialist at Neoretina Eyecare Institute, Hyderabad.

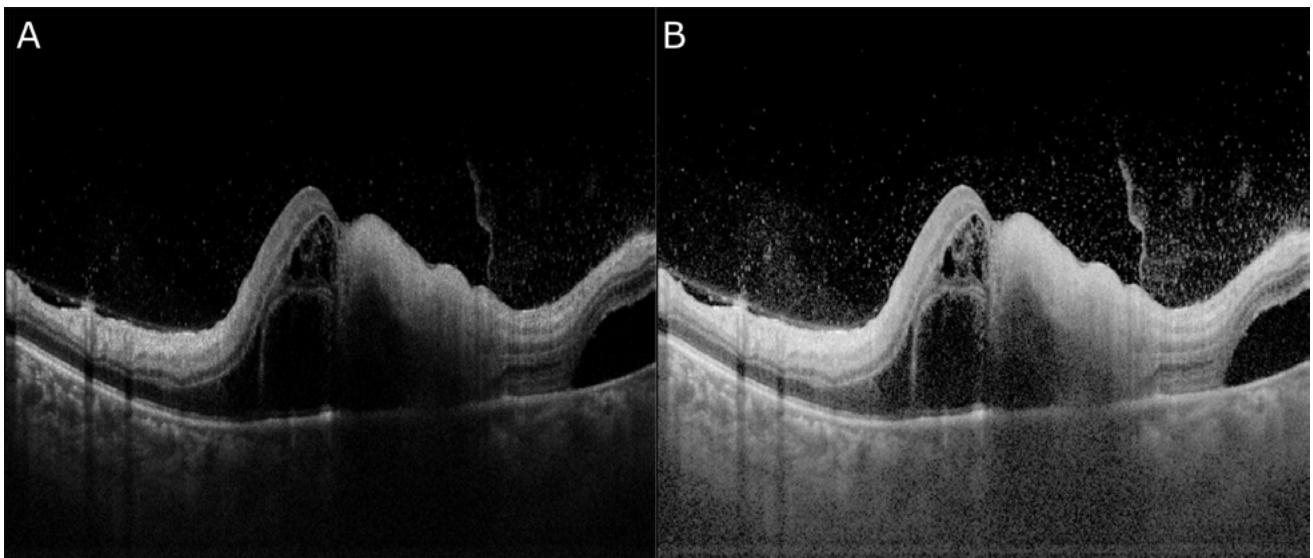
**Background:** Toxoplasma retinochoroiditis is the leading cause of posterior uveitis worldwide. Retinochoroiditis adjacent to a pigmented chorioretinal scar with moderate to severe vitritis is the classic clinical presentation of the disease and represents reactivation of a congenitally or postnatally acquired infection. Atypical presentations are also seen<sup>1</sup> and familiarity with uncommon presentations of this common disease might be useful in clinical practice in keeping a high index of suspicion. We present an interesting case of primary acquired toxoplasma retinochoroiditis which subsequently developed vitreomacular traction and has been followed up with swept source optical coherence tomography (SS-OCT).

**Case report:** A 21 year old female presented with rapid loss of vision in her left eye over the past 1 week. On examination her best corrected visual acuity (BCVA) was 6/6 (OD) and 6/60 (OS). Intraocular pressures were 16mmHg (OD) and 21mmHg (OS). Anterior segment slit lamp examination was unremarkable. Dilated fundus examination of the right eye was normal. Left eye revealed a yellowish white perifoveal lesion with surrounding subretinal exudation, adjacent arteritis and a localised vitritis. Fundus fluorescein angiography (FA) showed early hypofluorescence of the lesion with late hyperfluorescence and leakage of dye surrounding the area of hypofluorescence (Figure 1).



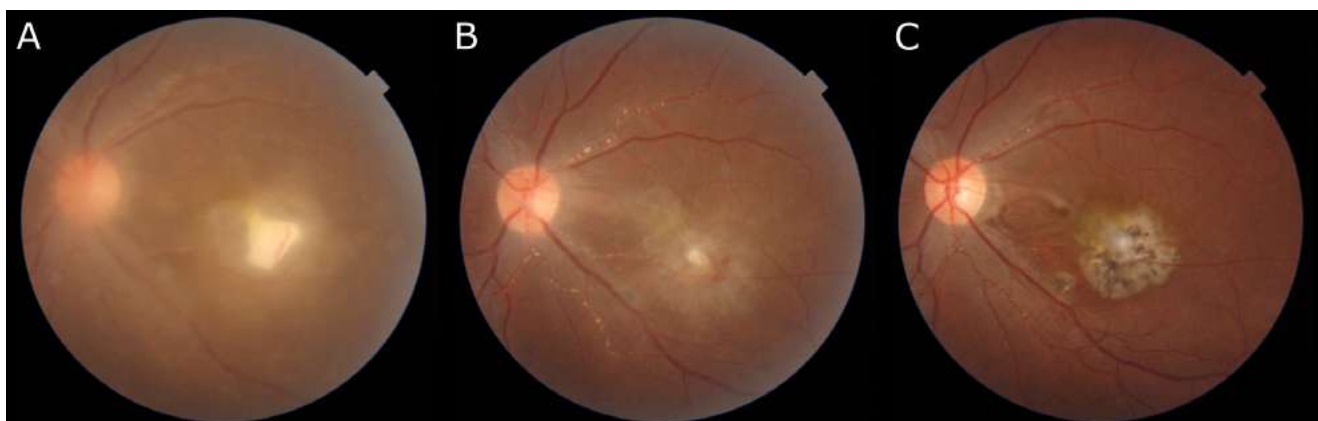
**Figure 1.** (A) Yellowish white perifoveal retinochoroiditis lesion with vitritis and adjacent arteritis.  
(B) FA showing early hypofluorescence and  
(C) Late leakage.

SS-OCT of the lesion revealed hyperreflectivity of all the retinal layers with shadowing of the underlying choroid. Thickened posterior hyaloid and vitritis were seen more evidently in the enhanced vitreous visualisation (EVV) mode (Figure 2).

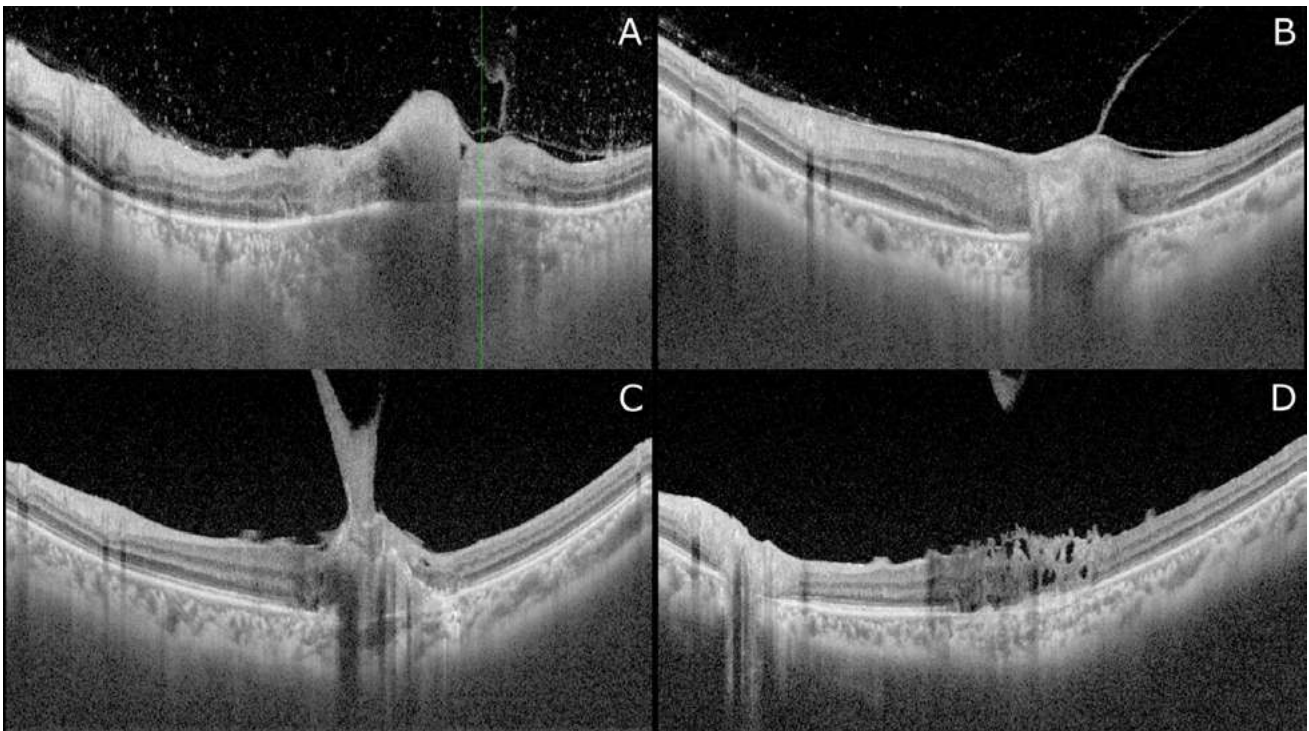


**Figure 2.** (A) Radial SS-OCT scan through the lesion at presentation showing hyperreflectivity of the retinal layers with shadowing of the choroid,

(B) Same scan in EVV mode with better visualisation of vitritis and a thickened posterior hyaloid. On serology, anti-toxoplasma (IgG and IgM) titres were raised and other common causes of infectious posterior uveitis were ruled out. Non-immunocompromised status was also confirmed. Patient gave history of exposure to cats as a child. Based on serology and absence of a pigmented chorioretinal scar in either eye, a diagnosis of primary acquired retinochoroiditis was made. Patient was started on oral Azithromycin and Co-trimoxazole. After 3 days of institution of antiparasitic treatment, intravenous methylprednisolone pulse therapy followed by tapering doses of oral steroids were added to the regimen. Follow up SS-OCT scans on day 13 and then day 55 showed progressive retinal scar formation, resolution of vitritis and development of vitreomacular traction (VMT). Her BCVA had improved to 6/18P with clinical resolution and she was advised periodical review. At 16 months' follow-up, her BCVA had improved to 6/12. However, fundus examination revealed a pigmented scar and SS-OCT showed a taut VMT and extensive loss of retinal architecture in the area of scarring (Figure 3 and Figure 4).



**Figure 3.** (A) Fundus photograph on Day 13  
 (B) Day 55  
 (C) At 16 months, showing progressive healing of the lesion with pigmented scar formation and VMT.



**Figure 4.** (A) Radial SS-OCT scan through the lesion in EVV mode on Day 13,  
 (B) Day 55  
 (C) at 16 months showing resolution of vitritis, progressive scar formation and a taut VMT at the last follow-up.  
 (D) SS-OCT in EVV mode through the pigmented scar showing loss of retinal architecture

**Discussion:** Contrary to the earlier belief, primary acquired disease accounts for many cases of toxoplasma retinochoroiditis<sup>1</sup>. Hence toxoplasmosis should be considered in the differential diagnosis of retinochoroiditis even in the absence of a pigmented chorioretinal scar. Apart from serology in such cases, imaging findings may also help at arriving at the diagnosis.

Characteristic FA findings of early hypofluorescence and surrounding late hyperfluorescence were seen in our case. Hyperreflectivity of the retinal layers with shadowing of the underlying choroid and a thickened and detached posterior hyaloid with localised vitritis are OCT findings described for active lesions of toxoplasma retinochoroiditis<sup>2,3</sup>. Shadowing in cases of toxoplasma retinochoroiditis is said to be more marked compared to that seen in other causes of retinitis<sup>2</sup>.

SS-OCT is a recent development in OCT characterised by a longer wavelength (1050nm) and lower axial sensitivity decay thereby bypassing the limitations of enhanced depth imaging OCT and allowing for complete evaluation of superficial and deep layers in the same scan. There have been very few studies of SS-OCT in toxoplasma retinochoroiditis<sup>3</sup>. In the present case, EVV mode on SS-OCT was used to enhance visualisation of the vitreous and vitreo-retinal interface and objectively document the resolution of vitritis.

Our case also demonstrated development of a progressive VMT. Though VMT has been previously reported<sup>4</sup>, it is not a common feature of toxoplasma retinochoroiditis. This might be because a taut posterior hyaloid subsequently gets detached, unlike in the present case where it led to VMT. Some patients with VMT and reduced visual acuity may require vitreo-retinal surgery<sup>5</sup>, hence follow up with

OCT even after resolution of active disease is important. In our case, BCVA had improved to 6/12 at 16 months' follow-up, even in the presence of a taut VMT. Hence, no intervention was planned and patient was advised periodical review.

**Conclusion:** Primary acquired toxoplasmosis should be kept in the differential diagnosis of retinochoroiditis with positive serology and suggestive imaging findings. SS-OCT is a useful non-invasive tool in the study and objective follow-up of cases of toxoplasma retinochoroiditis. Significant VMT might develop in cases of toxoplasma retinochoroiditis and should be followed up with serial OCT, even after clinical resolution of active disease.

#### **References:**

1. Smith JR, Cunningham ET. Atypical presentations of ocular toxoplasmosis. *Current Opinion in Ophthalmology*. 2002;13(6). [https://journals.lww.com/co-ophthalmology/Fulltext/2002/12000/Atypical\\_presentations\\_of\\_ocular\\_toxoplasmosis.8.aspx](https://journals.lww.com/co-ophthalmology/Fulltext/2002/12000/Atypical_presentations_of_ocular_toxoplasmosis.8.aspx).
2. Invernizzi A, Cozzi M, Staurenghi G. Optical coherence tomography and optical coherence tomography angiography in uveitis: A review. *Clinical & Experimental Ophthalmology*. 2019;47(3):357-371. doi:10.1111/ceo.13470
3. Vezzola D, Allegrini D, Borgia A, et al. Swept-source optical coherence tomography and optical coherence tomography angiography in acquired toxoplasmic chorioretinitis: a case report. *Journal of Medical Case Reports*. 2018;12(1):358. doi:10.1186/s13256-018-1902-x
4. Magliyah MSA, Al-Khars WI. Ocular toxoplasmosis related macular traction: A case report and review of the literature. *Saudi Journal of Ophthalmology*. 2019;33(1):84-87. doi:10.1016/j.sjopt.2018.07.002
5. Scarpa G, Fabris S, Di Gregorio M, Urban F. Late vitreomacular traction in toxoplasma retinochoroiditis resolved by vitrectomy. *Clin Ophthalmol*. 2013;7:1787–1789. doi:10.2147/OPTH.S44857

#### **Expert comments on this case by Dr. Avinash Pathengay**

In my practice , have not thought or felt a need about using IVMP in the management of ocular toxoplasmosis.

My practice would entail usage of oral corticosteroids for 2 weeks with no taper.

It would start 24 hours after initiation of Bactrim DS and continue for 2 weeks.

I also couple dexamethasone with intravitreal clindamycin.

We have given systemic steroids for longer duration wit tapering dose

#### **The most important points one need to consider:**

1. Toxoplasmosis is a slow growing organism.
2. Always cover the duration of corticosteroid action with anti toxoplasma treatment for eg : Intravitreal Dexamethasone works for 24 to 48 hrs whereas clindamycin works for 5 to 7 days.





# Recent Advances in Ocular Toxoplasmosis

Author:

Dr. Aniruddha Agarwal

## **Title: Recent Advances in Ocular Toxoplasmosis**

**Authors:** Aniruddha Agarwal, MD

Advanced Eye Center, Department of Ophthalmology, Post Graduate Institute of Medical Education and Research (PGIMER), Chandigarh, India

### **Address:**

Aniruddha Agarwal, MD

Assistant Professor of Ophthalmology

Advanced Eye Center, Department of Ophthalmology

Post Graduate Institute of Medical Education and Research (PGIMER)

Sector 12, Chandigarh

Phone: +91 172 2756111

Fax: +91 172 2756111

Email: [aniruddha9@gmail.com](mailto:aniruddha9@gmail.com)

### **Ocular Toxoplasmosis: Epidemiological Aspects**

Toxoplasmosis is a systemic disease caused by the obligate intracellular protozoan parasite *Toxoplasma gondii* that affects both humans and animals. Members of the Felidae (cat) family serve as definitive hosts.<sup>1</sup> In the United States, the Centers for Disease Control has estimated that 22.5% of the population who are 12 years and older have been infected with *T. gondii* and up to 10% of infected individuals present with retinal lesions.<sup>2</sup> In a study from North India, the estimated incidence of posterior uveitis due to toxoplasmosis was 3% in adults.<sup>3</sup>

### **Genetic Susceptibility of Toxoplasmosis**

There has been significant advancement of knowledge regarding the genetic susceptibility of individuals for toxoplasmosis. Significant association of HLADQ3 with congenital ocular toxoplasmosis, hydrocephalus, and encephalitis has been observed. HLA-B35 has been associated with a risk of progressive retinitis. Genetic polymorphisms (including IFN- $\gamma$  and other genes) also confer a higher risk of infection. HLA-B62 is associated with a high risk of "acute necrotizing retinitis syndrome".<sup>4</sup>

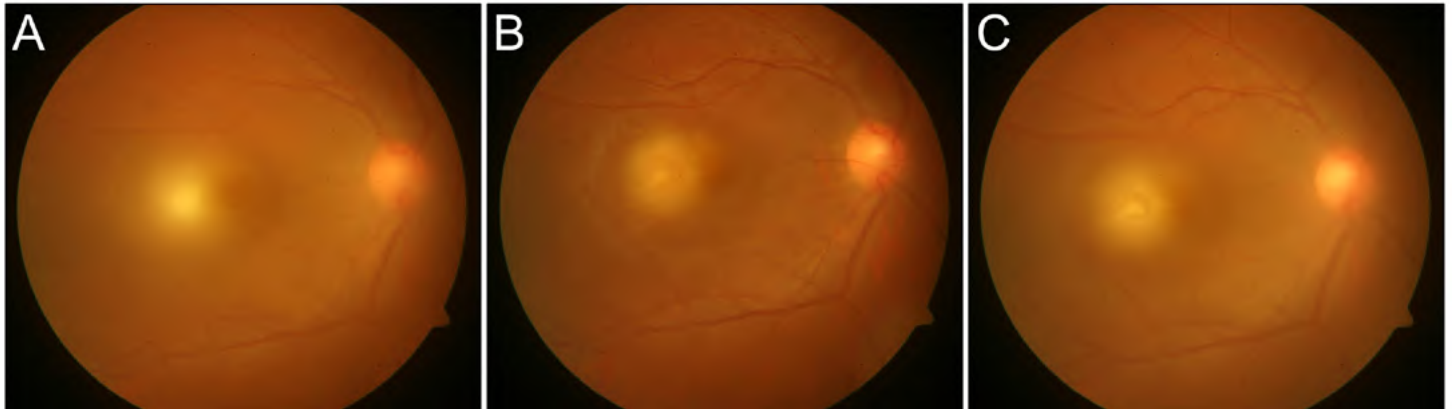### **Features of Ocular Toxoplasmosis**

Ocular involvement can be a result of acquired infection or, more commonly, a recurrence of the congenital form of the disease. Ocular toxoplasmosis associated with congenital *T. gondii* infections can be apparent at birth, either as active retinal lesions or as healed retinochoroidal scars. Various clinical manifestations of ocular toxoplasmosis include: retinochoroiditis, vasculitis, vascular occlusion, papillitis, and neuroretinitis.<sup>5</sup>

Classically, lesions of *Toxoplasma* retinochoroiditis appear as foci of inner retinitis adjacent to an old chorioretinal scar, and are accompanied by dense focal vitritis (*headlight in fog* appearance). In primary acquired disease, the retinitis is seen without the presence of any previous scar. Recurrences manifest as '*satellite lesions*' at a border of preexisting retinochoroidal scars with variable pigmentation. However,

in some patients, new '*primary retinal lesions*' (defined as those not arising from retinochoroidal scars) can develop far away from the preexisting scars, in areas of retina that had appeared clinically normal. Recurrences are unpredictable and can occur months to years after the resolution of the primary lesion.<sup>6</sup> The typical lesion is a yellowish-white area of necrotizing retinitis with poorly defined margins due to surrounding edema (Figure 1).

**Figure 1:** Fundus photograph of a typical macular retinochoroiditis lesion caused by toxoplasmosis at baseline (A). The lesion appears as a yellow-white area of retinitis with surrounding retinal edema and dense vitritis overlying the lesion (headlight in fog) appearance. Over 4 weeks of therapy, the lesion has become more well-defined with distinct margins, and there is an interval reduction in the vitritis (B). Over another 4 weeks, the lesion shows further improvement and healing (C).



The lesion is frequently located in the macula or posterior to the equator but may occur in the periphery. The edges of the lesion gradually become well-defined and the lesion progressively heals from periphery towards the center leaving behind a scar tissue. The scar gets progressively pigmented starting at the edges. The average time for the scarring of an active lesion often appears to be related to the lesion size and immune status of the host; resolution often occurs in approximately 3–4 weeks. With prompt diagnosis and treatment, lesions may resolve more rapidly. In an immunocompromised host, the disease may have bilateral presentation and multiple foci in one eye. The lesions tend to enlarge progressively resembling viral retinitis.<sup>6,7</sup>

### **Morphological Forms of Ocular Toxoplasmosis**

Three distinct morphologic forms of ocular toxoplasmosis have been described:<sup>8</sup>

1. Large destructive lesions
2. Punctate inner lesions
3. Punctate outer lesions

Vasculitis may be associated with the retinochoroiditis lesion (*Kyrieleis' vasculitis*). Periphlebitis is more frequent than arteritis; retinal hemorrhages may also be seen. Papillitis, juxtapapillary chorioretinitis, and neuroretinitis are the less common clinical manifestations of ocular toxoplasmosis.<sup>5,6</sup>

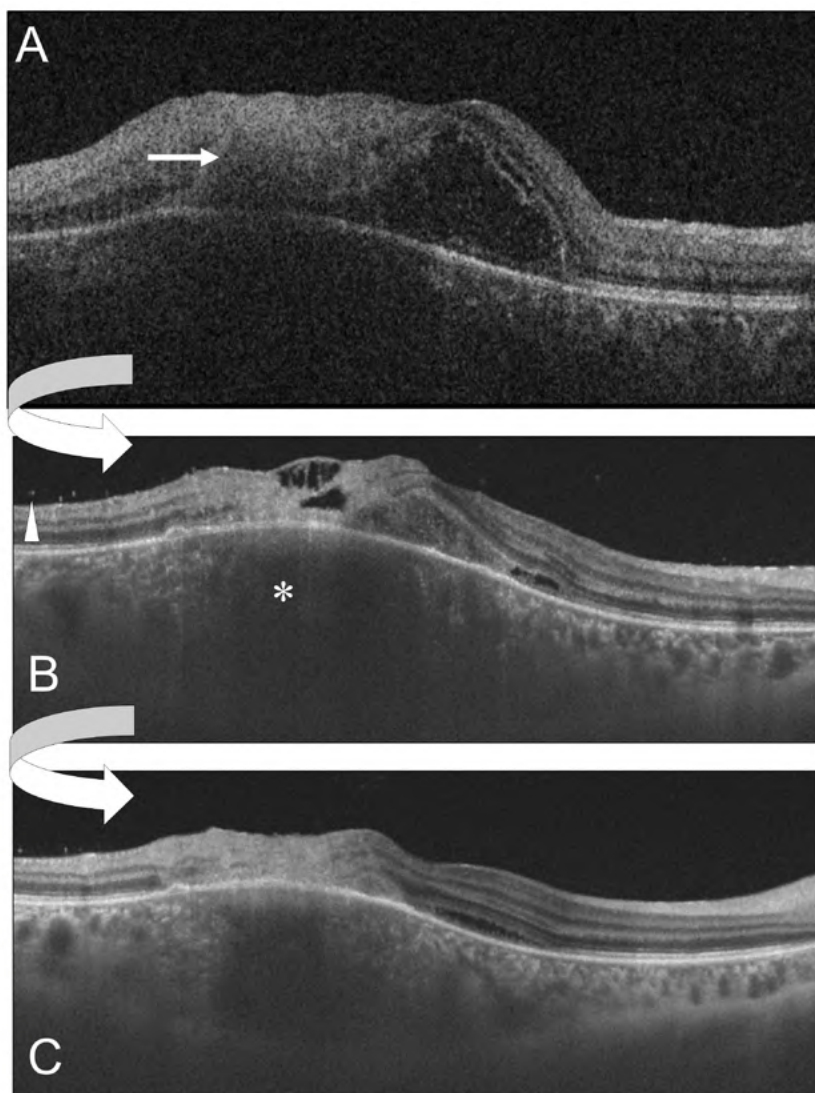
## What is New in the Imaging of Ocular Toxoplasmosis?

### Optical Coherence Tomography

Optical Coherence Tomography (OCT) is helpful in identifying the features, extent, and location of retinitis caused by toxoplasmosis and may be helpful in the visualization of the toxoplasmosis cyst or granuloma (Table 1). In addition, OCT helps assessing the progression of the disease and development of complications and provides information regarding the visual prognosis.<sup>9-11</sup>

**Active lesion:** Active lesions of chorioretinitis show thickening and hyperreflectivity of the neurosensory retina, disruption of the photoreceptor inner/outer segment junction, choroidal shadowing and elevation of the RPE (Figure 2).

**Figure 2:** Serial optical coherence tomography (OCT) of a young girl with ocular toxoplasmosis shows presence of a typical retinochoroiditis lesion with full thickness retinal necrosis and thickening (white arrow) (A). There is intraretinal edema and fluid, and significant local choroidal thickening due to underlying inflammation and infection due to the parasite. Four weeks after therapy (B), the full thickness retinitis lesion has decreased in size, there is a reduction in retinal edema and thickness, and reduction in choroidal inflammation (white asterisk). The retrohyaloid cells are seen (white arrowhead). The OCT scan at 8 weeks from presentation shows further healing and reduction in retinal thickness and choroidal swelling (C).



Choroidal thickening may occur beneath the active lesion in the acute phase which subsequently returns to normal values as the inflammation resolves. It is also useful to detect subtle serous retinal detachment triggered by active retinochoroiditis or to detect subretinal new vessel formation.<sup>9,10</sup>

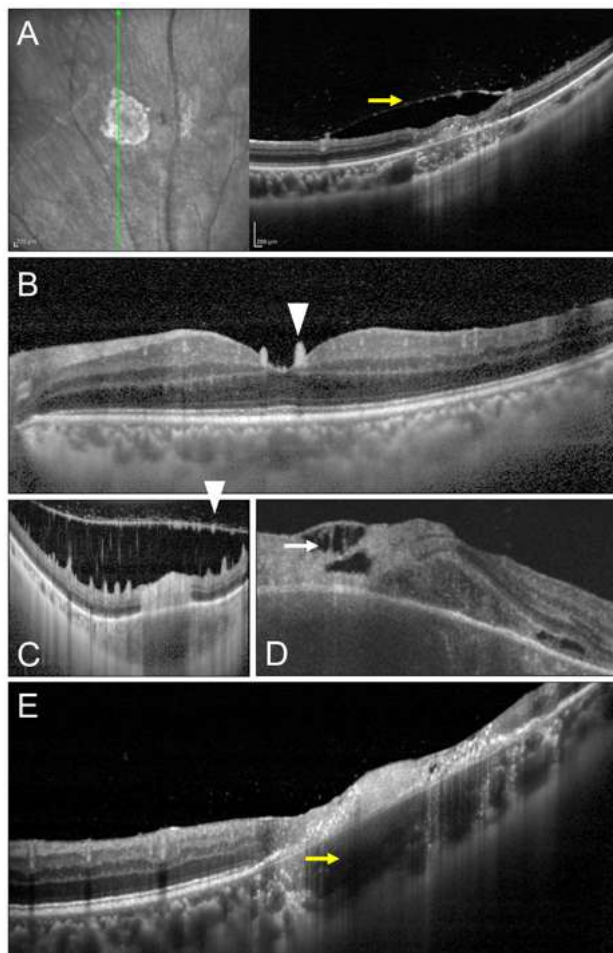
**Healed lesion:** OCT through the site of healed lesion demonstrates thinning of the neurosensory retina, and disorganization of photoreceptor and RPE layer. Disruption of the photoreceptor layer can be helpful in predicting the visual prognosis (Figure 2).

OCT Signs in Toxoplasmosis	% of Cases
Vitritis	90
Hyaloid thickening	100
Retinal disruption	100
Retinal thickening	100
Retinal hyper-reflectivity	100
Interruption of photoreceptors IS/OS	100
RPE elevation	100
Hyper-reflective oval deposits	60
Subretinal Fluid	20
Hypo-reflectivity of the choroid	100

The novel signs of ocular toxoplasmosis on OCT include the following (Table 2; Figure 3):<sup>11</sup>

OCT Signs in Toxoplasmosis	% of Cases
Clots of cells along the posterior Hyaloid	10-20
Retro-hyaloid hyper-reflective spots	10-20
Hyper-reflective oval deposits	60-80
Hypo-reflectivity of the choroid	100

**Figure 3:** Novel features of toxoplasma retinochoroiditis seen on optical coherence tomography (OCT) are highlighted in Figure 3. (A) OCT scan shows presence of a thick detached hyaloid with cellular infiltration (yellow arrow). OCT scan of another patient (B) shows presence of typical stalagmite collection of inflammatory material on the retinal surface (white arrowhead). These hyper-reflective deposits may have mirror imaged deposits on the hyaloid (C) (white arrowhead). Intraretinal edema and fluid is marked by a white arrow (D). The choroidal inflammation and thickening (appearing as a dense hyporeflective lesion) is marked by a yellow arrow (E).



### Novel Laboratory Diagnosis of Ocular Toxoplasmosis

The diagnosis of ocular toxoplasmosis is typically clinical. However, there may be cases with atypical presentation and lesions that may present as a diagnostic challenge, often confusing with entities such as viral retinitis. The role of serum immunoglobulins (Ig) are usually supportive, wherein IgM indicates recent infection. Usually, patients with ocular toxoplasmosis must have at least an IgG positivity from serum if they are immunocompetent. The detection of IgM and IgG can be done using techniques such as ELISA, or immunofluorescent antibody kits available commercially.<sup>12</sup>

Intraocular antibody production can be determined using Goldmann-Witmer coefficient (GWC). GWC from the aqueous humor may be a very sensitive test for the detection of toxoplasmosis.<sup>13</sup>

Polymerase chain reaction (PCR) is a useful diagnostic test that determines the presence of toxoplasma DNA in the vitreous or aqueous. The main issue with PCR for toxoplasmosis is the lack of sensitivity, which ranges usually from 27-36% (though the specificity is 100%). One strategy of improving the sensitivity of PCR is by combining GWC with PCR which increases sensitivity to 81-93%.<sup>14</sup> Sugita et al have suggested a two-step PCR technique for better detection of toxoplasma DNA. The first step consists of qualitative multiplex PCR for detection of the genome, and a quantitative real-time PCR as a second step. This strategy provides a sensitivity of 85%.<sup>15</sup>

## Treatment of Ocular Toxoplasmosis

### 1. Conventional Systemic Approach to Therapy

The most commonly employed treatment strategy for acute *Toxoplasma* retinochoroiditis is systemic administration of one or more antibiotics usually given for 4 to 8 weeks.<sup>16</sup> The terms, 'classic therapy' or 'triple-drug therapy' refers to the combination of pyrimethamine (25 mg-50 mg daily orally in one to two doses) and sulfadiazine along with corticosteroids and folinic acid. An alternative to classic treatment, trimethoprim-sulfamethoxazole (160 mg-800 mg twice daily orally) is an attractive option for reasons that include low cost, wide availability and tolerability though sulfonamide-related reactions may occur. Studies have indicated that trimethoprim/ sulfamethoxazole/ prednisone is an acceptable alternative to classic therapy. This combination may also have a role in the prevention of recurrent attacks of ocular toxoplasmosis.<sup>17</sup>

Clindamycin (300 mg orally four times daily) is a lincosamide antibiotic that interferes with translation of the apicoplast, which is an unusual plastid-like organelle found in *T. gondii*. The drug is often added to triple therapy, which is then referred to as 'quadruple therapy'.<sup>16</sup> In pregnant women, spiramycin is usually preferred if the women becomes infected up to 18 weeks into pregnancy or within 6 months prior to conception. Local therapies can also be considered in conditions where systemic therapy may be contra indicated.

### 2. Novel Therapeutic Agents for Ocular Toxoplasmosis

Dihydrothiazine is a new dihydrofolate reductase inhibitor that has been shown to be more effective than pyrimethamine in the parasitocidal action against toxoplasmosis. Given either orally or intravitreally, this agent acts against all clonal forms of toxoplasmosis and may be more effective than other agents of this class.<sup>18</sup> Antimalarial drugs have also shown to be efficacious against toxoplasmosis. Artemisinin derivatives such as artimisine and artemisone have been tested and shown to be efficacious in controlling parasite replication.<sup>19</sup>

Techniques of subtractive genomics has been useful in drug development against toxoplasmosis. This technique pertains to subtraction of sequences between host and the pathogen proteome which helps in providing information for a set of proteins which are essential to pathogen but are not present in the host. Subtractive genomic studies revealed presence of several apicoplast therapeutic targets for toxoplasmosis.<sup>20</sup>

Further, studies have elucidated the role of abscisic acid, an endogenous hormone that controls the intracellular calcium secretion of the parasite. This calcium release controls the cell invasion and motility of the parasite. Fluridone is an agent that inhibits abscisic acid and has been shown to reduce parasite load and cyst formation in central nervous system toxoplasmosis in mice models. This agent demonstrated low toxicity in mammalian studies.<sup>21</sup>

There are also several *Toxoplasma* calcium-dependent protein kinases that can be used as therapeutic targets for toxoplasmosis. The calcium-dependent protein kinases are highly vulnerable to drugs as they contain a unique sequence variation in the ATP binding pocket that distinguishes them from all known mammalian kinases.<sup>22</sup>

### **Intravitreal Therapy for Ocular Toxoplasmosis**

The intravitreal therapy for toxoplasma retinochoroiditis consists of a combination of intravitreal clindamycin (1 mg/0.1 ml) with dexamethasone. This therapy can be given in all cases and is comparable with systemic clindamycin, or other therapies for toxoplasmosis, though clinical trials comparing the efficacy have not yet been performed. Intravitreal injections can be given bi-weekly or every week till the resolution of the lesions.<sup>23,24</sup>

### **Prophylaxis for Toxoplasmosis: Is it a Possibility?**

An antimalarial agent, atovaquone, is the only available drug that can help in prolonging the time to recurrence of toxoplasmosis. For ocular toxoplasmosis, no agent is routinely available or used to prevent future recurrences, unlike in the cases of viral uveitis. This is mainly because the clinical utility of such prophylactic agents has yet to be established in large clinical trials. Moreover, drugs such as trimethoprim-sulfamethoxazole combination can also be easily used to treat, or reduce the recurrences.

### **Vaccination Strategies for Toxoplasmosis: An Option for the Future?**

Since more than one-third global population is exposed to toxoplasma parasite, there has been significant interest in development of a vaccination against toxoplasmosis. A number of vaccines such as nucleic acid vaccines, recombinant protein vaccines, live attenuated vaccines, and inactivated whole pathogen vaccines have been studied. Presently, the major challenge in developing a new toxoplasmosis vaccine is to acquire both sterile protection and high safety standards. DNA vaccines for toxoplasmosis are most popular and have many advantages in terms of safety, rapid production, stable storage and effective stimulation of both humoral and cellular immune responses. Vaccines targeting the Rhoptry (ROP) proteins appear to be very attractive options. ROP18 is tachyzoite-specific antigen which appears to be a promising antigen to provide cross-protection against both tachyzoites and bradyzoites.<sup>25</sup>

### **Conclusions**

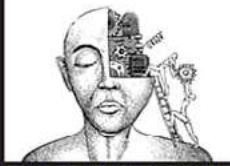
In conclusion, despite the common practice of treating Toxoplasma retinochoroiditis with systemic antibiotics, there are no randomized controlled trials demonstrating that antibiotic treatment improves long-term visual outcomes. Also, there is no convincing evidence to date that treatment decreases the severity of intraocular inflammation or duration of disease for all patients.



## References

1. Butler NJ, Furtado JM, Winthrop KL, Smith JR. Ocular toxoplasmosis II: clinical features, pathology and management. *Clin Experiment Ophthalmol*. 2013;41(1):95-108. doi:10.1111/j.1442-9071.2012.02838.x
2. Holland GN. Ocular toxoplasmosis: a global reassessment. Part I: epidemiology and course of disease. *Am J Ophthalmol*. 2003;136(6):973-988. doi:10.1016/j.ajo.2003.09.040
3. Dogra M, Singh R, Agarwal A, et al. Epidemiology of Uveitis in a Tertiary-care Referral Institute in North India. *Ocul Immunol Inflamm*. 2017;25(sup1):S46-S53. doi:10.1080/09273948.2016.1255761
4. Lu F, Huang S, Hu MS, Kasper LH. Experimental Ocular Toxoplasmosis in Genetically Susceptible and Resistant Mice. *Infect Immun*. 2005;73(8):5160-5165. doi:10.1128/IAI.73.8.5160-5165.2005
5. Antoniazzi E, Guagliano R, Meroni V, Pezzotta S, Bianchi PE. Ocular impairment of toxoplasmosis. *Parassitologia*. 2008;50(1-2):35-36.
6. Vasconcelos-Santos DV. Ocular manifestations of systemic disease: toxoplasmosis. *Curr Opin Ophthalmol*. 2012;23(6):543-550. doi:10.1097/ICU.0b013e328358bae5
7. Maenz M, Schlüter D, Liesenfeld O, Schares G, Gross U, Pleyer U. Ocular toxoplasmosis past, present and new aspects of an old disease. *Prog Retin Eye Res*. 2014;39:77-106. doi:10.1016/j.preteyeres.2013.12.005
8. Friedmann CT, Knox DL. Variations in recurrent active toxoplasmic retinochoroiditis. *Arch Ophthalmol*. 1969;81(4):481-493. doi:10.1001/archopht.1969.00990010483005
9. Goldenberg D, Goldstein M, Loewenstein A, Habet-Wilner Z. Vitreal, retinal, and choroidal findings in active and scarred toxoplasmosis lesions: a prospective study by spectral-domain optical coherence tomography. *Graefes Arch Clin Exp Ophthalmol*. 2013;251(8):2037-2045. doi:10.1007/s00417-013-2334-3
10. Alwassia AA, Cho H, Adhi M, Duker JS, Baumal CR. Sequential optical coherence tomography images of retinal necrosis in acute ocular toxoplasmosis. *Retin Cases Brief Rep*. 2013;7(1):98-101. doi:10.1097/ICB.0b013e31826f093b
11. Invernizzi A, Agarwal AK, Ravera V, et al. Comparing optical coherence tomography findings in different aetiologies of infectious necrotising retinitis. *Br J Ophthalmol*. 2018;102(4):433-437. doi:10.1136/bjophthalmol-2017-310210
12. Ozgonul C, Besirli CG. Recent Developments in the Diagnosis and Treatment of Ocular Toxoplasmosis. *Ophthalmic Res*. 2017;57(1):1-12. doi:10.1159/000449169
13. Suzuki LA, Rocha RJ, Rossi CL. Evaluation of serological markers for the immunodiagnosis of acute acquired toxoplasmosis. *J Med Microbiol*. 2001;50(1):62-70. doi:10.1099/0022-1317-50-1-62
14. Fekkar A, Bodaghi B, Touafek F, Le Hoang P, Mazier D, Paris L. Comparison of immunoblotting, calculation of the Goldmann-Witmer coefficient, and real-time PCR using aqueous humor samples for diagnosis of ocular toxoplasmosis. *J Clin Microbiol*. 2008;46(6):1965-1967. doi:10.1128/JCM.01900-07

15. Sugita S, Ogawa M, Inoue S, Shimizu N, Mochizuki M. Diagnosis of ocular toxoplasmosis by two polymerase chain reaction (PCR) examinations: qualitative multiplex and quantitative real-time. *Jpn J Ophthalmol*. 2011;55(5):495-501. doi:10.1007/s10384-011-0065-8
16. Rothova A, Meenken C, Buitenhuis HJ, et al. Therapy for ocular toxoplasmosis. *Am J Ophthalmol*. 1993;115(4):517-523. doi:10.1016/s0002-9394(14)74456-3
17. Silveira C, Muccioli C, Nussenblatt R, Belfort R. The Effect of Long-term Intermittent Trimethoprim/Sulfamethoxazole Treatment on Recurrences of Toxoplasmic Retinochoroiditis: 10 Years of Follow-up. *Ocul Immunol Inflamm*. 2015;23(3):246-247. doi:10.3109/09273948.2014.964422
18. Mui EJ, Schiehser GA, Milhous WK, et al. Novel triazine JPC-2067-B inhibits *Toxoplasma gondii* in vitro and in vivo. *PLoS Negl Trop Dis*. 2008;2(3):e190. doi:10.1371/journal.pntd.0000190
19. Dunay IR, Chan WC, Haynes RK, Sibley LD. Artemisone and artemiside control acute and reactivated toxoplasmosis in a murine model. *Antimicrob Agents Chemother*. 2009;53(10):4450-4456. doi:10.1128/AAC.00502-09
20. Saremy S, Boroujeni ME, Bhattacharjee B, Mittal V, Chatterjee J. Identification of potential apicoplast associated therapeutic targets in human and animal pathogen *Toxoplasma gondii* ME49. *Bioinformatics*. 2011;7(8):379-383. doi:10.6026/97320630007379
21. Nagamune K, Hicks LM, Fux B, Brossier F, Chini EN, Sibley LD. Abscisic acid controls calcium-dependent egress and development in *Toxoplasma gondii*. *Nature*. 2008;451(7175):207-210. doi:10.1038/nature06478
22. Ojo KK, Larson ET, Keyloun KR, et al. *Toxoplasma gondii* calcium-dependent protein kinase 1 is a target for selective kinase inhibitors. *Nat Struct Mol Biol*. 2010;17(5):602-607. doi:10.1038/nsmb.1818
23. Baharivand N, Mahdavi-fard A, Fouladi RF. Intravitreal clindamycin plus dexamethasone versus classic oral therapy in toxoplasmic retinochoroiditis: a prospective randomized clinical trial. *Int Ophthalmol*. 2013;33(1):39-46. doi:10.1007/s10792-012-9634-1
24. Kishore K, Jain S, Zarbin MA. Intravitreal ganciclovir and dexamethasone as adjunctive therapy in the management of acute retinal necrosis caused by varicella zoster virus. *Ophthalmic Surg Lasers Imaging*. 2011;42 Online:e87-90. doi:10.3928/15428877-20110901-06
25. Loh F-K, Nathan S, Chow S-C, Fang C-M. Vaccination challenges and strategies against long-lived *Toxoplasma gondii*. *Vaccine*. 2019;37(30):3989-4000. doi:10.1016/j.vaccine.2019.05.083



Cogito ergo sum: I think, therefore I am

# UVEITIS UNCODED 2

22-23 February 2020



## Day 1

### Imaging in Uveitis - Made Easy

B scan Simplified  
OCT Untangled  
Deciphering FFA and ICGA

### Imaging and Interventions in Uveitis - Breakout Session

Participants will be divided into smaller groups for teaching/discussion of diagnostic modalities

How to Use Steroids in Uveitis

### Register Online

Contact: Dr Hrishikesh Kaza & Dr Bhavik Panchal  
Email: hrishikesh.kaza@gmail.com, drbhavikpanchal@gmail.com, lokesh@lvpei.org

## Day 2

### Problem Based Learning (PBL) - Interactive

PBL 1 - Anterior Uveitis  
PBL 2 - Intermediate Uveitis  
PBL 3 - Retinitis

PBL 4 - Unifocal Choroiditis  
PBL 5 - Multifocal Choroiditis  
PBL 6 - Panuveitis

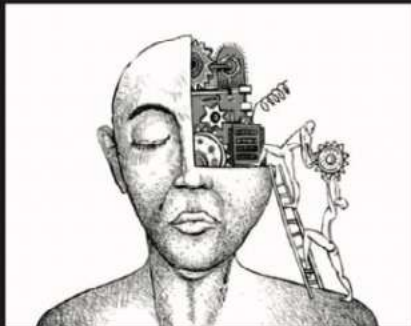
PBL 7 - Retinal Vasculitis

Fees - ₹ 10,000

Venue:  
LVPEI Visakhapatnam

# UVEITIS UNCODED 2

22-23 February 2020



Cogito ergo sum: I think, therefore I am

30  
slots  
available

## Personalized interaction involving

- Skill transfer sessions  
FFA/OCT/USG
- Wet Lab for intravitreal injections
- Role of steroids:  
Topical/periorcular/ intraocular/  
systemic
- Problem-based learning
- Clinical pearls

Attending UVEITIS UNCODED 2  
will add meaning to your uveitis practice!

**Registration fees - ₹ 10,000/-**

## Register Online

Contact: Dr Hrishikesh Kaza & Dr Bhavik Panchal  
Email: hrishikesh.kaza@gmail.com, drbhavikpanchal@gmail.com, lokesh@lvpei.org

Venue:  
LVPEI Campus, Visakhapatnam

# IGNITE 2020



Ignite 2020; CME on ocular inflammation and uveitis, conducted by Amrita Institute of Medical Sciences, and Cochin Uveitis Group under the aegis of Uveitis Society of India, Kerala Society of Ophthalmic Surgeons and Cochin Ophthalmic Club was conducted on 12th Jan 2020 at IMA House, Cochin. The CME was also the inaugural meeting of the Kerala uveitis Interest group, started to promote knowledge about uveitic disorders among general ophthalmologists and to increase interactive sessions on the subject.

The event was a star studded one – with giants such as Dr. Somasheila Murthy (Head – Cornea Services, LVPEI and Ex- USI office bearer), Dr. Kalpana Babu Murthy (Uveitis Consultant, Prabha Eye Clinic, Bangalore and Vice President, USI), Dr. Soumyava Basu (Head, Uveitis Services, LVPEI) in attendance, sharing their treasure trove of knowledge with the delegates. The highlight of the CME was the unique Uvea Rheumatology Interface – a session featuring prominent rheumatologists; Dr. Suma Balan (Pediatric Rheumatologist, AIMS Kochi), Dr. Mithun C.B. (Adult Rheumatologist, AIMS Kochi), and Dr. Shanoj K.C. (Consultant Rheumatologist, CARE Hospital). Prominent faculty from the state and from AIMS joined them in the scientific deliberations. There were over 150 delegates in attendance from all over Kerala, who were treated to a feast of scientific talks, interactive case presentations, panel discussions and heated debates.

The CME was well appreciated by the audience, and KUIG hopes to continue it as an annual event.

# USICON 2019 - Bengaluru

The 19th Annual conference of Uveitis Society of India ,USICON 2019 was organised jointly by Dr. Padmamalini Mahendradas from Narayana Nethralaya ,Bengaluru and Dr. Kalpana Babu from Prabha Eye Clinic and Research Centre, Bengaluru from 20th to 22 nd September, 2019 at Sheraton Grand Brigade Gateway, Bengaluru. Dr. Narsing A Rao, Chief In patron of the society gave the welcome address for this meeting. Fourteen international faculty participated in this meeting . For the first time, Uvea Rheumatology interface session was conducted in the uveitis society of india meeting. We had seven rheumatologists as an invited faculty including Dr. A V Ramanan from Bristol .We had 44 national faculty along with 262 delegates participation in this meeting. Highlights of this meeting included Uvea Rheumatology Interface sessions, Hands on workshop on intravitreal injections and imaging, meditation class, photography contest and uveitis quiz for the first time in our annual meetings. Dr. Narsing A Rao best paper was won by Dr. Rupesh Agrawal, Dr. Carl Herbort second best paper award by Dr. Somasheila Murthy. Best Poster award by Dr. Nitin Kumar and Photography competition by Dr. Ankush Kawali.





## Prize Winners at the USICON 2019 - Bengaluru

### Dr. Narsing A Rao Award for Free Paper

**Dr. Rupesh Agrawal** – National health care group eye institute , Tan Tock Hospital, Singapore

**For Paper Titled:** “Standardization of nomenclature for ocular tuberculosis – Results of Collaborative Ocular Tuberculosis Study (COTS) Consensus (CON) Nomenclature Workshop”.

### Dr. Carl Herbolt Travel Grant Award for Free Paper

**Dr. Somasheila Murthy** – LVPEI, Hyderabad

**For Paper Titled:** “Utility of Anterior Segment Optical Coherence Tomography (ASOCT) in the Diagnosis of anterior Scleritis”.

### Photography Contest – Winner

**Dr. Ankush Kawali** - Narayana Nethralaya , Bengaluru

**Photo Titled:** “Petaloid Lymphoma”

### Poster Prize Winner

**Dr. Nitin Kumar** - Post Graduate Institute of Medical Education and Research, Chandigarh, India

**For Poster Titled:** Outcomes of Patients on Second-Line Anti-Tubercular Therapy for Rifampin Resistance Detected Using rpoB Gene Sequencing.





# USICON2019







*Congratulations*

**Dr. S R Rathinam**

**nominated as**

**"Unsung Hero of Uveitis"**

**by American Academy of Ophthalmology**



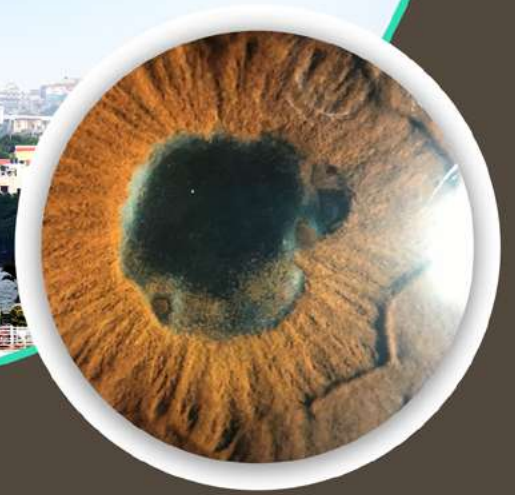Uveitis Society (India)



LV Prasad Eye Institute

# USICON 2020

9<sup>th</sup> | 10<sup>th</sup> | 11<sup>th</sup> October, Hyderabad



**BLOCK  
YOUR  
DATES**

Organizing Committee

Dr. Mudit Tyagi | Dr. Somasheila Murthy | Dr. Soumyava Basu



Await more details on  
[www.indianuveitis.org](http://www.indianuveitis.org)






## Address for Communication

Uveitis Society (India)

C/O Hallmark Events, Maruthi ' 688

1st floor, 6th main, 3rd block, BEL layout

Vidyaranyapura, Bangalore - 560097

 080 - 23646880

 9591732274

 [uveitissociety@gmail.com](mailto:uveitissociety@gmail.com)